ISSN 1814-6023 (Print)
ISSN 2524-2350 (Online)
UDC 616.728.3-018.38-073.8
https://doi.org/10.29235/1814-6023-2021-18-1-58-68 Received 12.07.2020

Oleksandr O. Kostrub[1], Viktor V. Kotiuk[1], Iurii V. Poliachenko[1], Mikhail A. Gerasimenko[2], Roman I. Blonskyi[1], Ivan A. Zasadnyuk[1]

[1]Institute of Traumatology and Orthopedics of the National Academy of Medical Sciences of Ukraine, Kyiv, Ukraine
[2]Republican Scientific and Practical Center of Traumatology and Orthopedics, Minsk, Republic of Belarus

VARIABILITY OF ANTEROLATERAL LIGAMENT ON MRI IMAGES – LACK OF SURVEY STANDARDIZATION OR ANATOMICAL VARIANTS?

Abstract. The anterolateral ligament is a rotational stabilizer of the knee joint. It is not always clear what we actually see on MRI in the area of anterolateral ligament (ALL).

The aim of the study was to evaluate the ALL variants on MRI images to summarize their common features and differences, and to try to find an explanation for the phenomenon of the ALL variability.

200 series of MRI images of knee joints were analyzed. The presence of the ALL, the number of its layers, the relation to the joint capsule, and other anatomical features were assessed.

The ALL was visualized on MRI at least partially in 88 % of cases. At least partially two-layer structure was detected in 68 % of all 200 MRI series. The wavy appearance of the certain portions of the anterolateral ligament was observed in some normal knee joints without a history of injuries.

Determined that the ALL is a separate anatomical element of the knee joint that has a variable, but in most cases two-layered, anatomical structure and can be detected on MRI in at least 88 % of cases. Axial sections help to identify ALL in complex cases and allow analyzing its anatomy, but adding little in the diagnosis of ALL injury.

Keywords: anterolateral ligament, MRI, anatomy, injuries, knee joint, rotational stability

For citation: Kostrub O. O., Kotiuk V. V., Poliachenko Iu. V., Gerasimenko M. A., Blonskyi R. I., Zasadnyuk I. A. Variability of anterolateral ligament on MRI images – lack of survey standardization or anatomical variants? *Vestsi Natsyyanal'nai akademii navuk Belarusi. Seriya meditsinskikh navuk = Proceedings of the National Academy of Sciences of Belarus. Medical series*, 2021, vol. 18, no. 1, pp. 58–68. https://doi.org/10.29235/1814-6023-2021-18-1-58-68

А. А. Коструб[1], В. В. Котюк[1], Ю. В. Поляченко[1], М. А. Герасименко[2], Р. И. Блонский[1], И. А. Засаднюк[1]

[1]Институт травматологии и ортопедии НАМН Украины, Киев, Украина
[2]Республиканский научно-практический центр травматологии и ортопедии, Минск, Республика Беларусь

ВАРИАБЕЛЬНОСТЬ АНТЕРОЛАТЕРАЛЬНОЙ СВЯЗКИ НА МРТ – ОТСУТСТВИЕ СТАНДАРТИЗАЦИИ ИССЛЕДОВАНИЙ ИЛИ ВАРИАНТЫ АНАТОМИИ?

Аннотация. Антеролатеральная связка является ротационным стабилизатором коленного сустава. Однако не всегда ясно, что мы видим на МРТ в этой области.

Цель исследования – оценить с помощью МРТ-изображений варианты антеролатеральной связки для выявления их общих черт и отличий и попытаться найти объяснение феномену этой вариабельности.

Проанализировано 200 серий МРТ-изображений коленных суставов. Оценено наличие антеролатеральной связки, количество ее слоев, взаимосвязь с капсулой сустава и другие анатомические особенности.

Антеролатеральная связка визуализировалась на МРТ хотя бы частично в 88 % случаев. По крайней мере частичная двухслойная структура была обнаружена в 68 % из всех 200 серий МРТ. Волнообразный вид некоторых частей антеролатеральной связки наблюдался в некоторых нормальных коленных суставах без травм в анамнезе.

В ходе исследований установлено, что антеролатеральная связка является отдельным анатомическим элементом коленного сустава, который имеет вариабельную, преимущественно двухслойную, анатомическую структуру и может быть обнаружена на МРТ по меньшей мере в 88 % случаев. Аксиальные срезы позволяют идентифицировать антеролатеральную связку в сложных случаях и проанализировать ее анатомию, но малоинформативны в плане диагностики ее повреждений.

Ключевые слова: антеролатеральная связка, МРТ, анатомия, повреждение, коленный сустав, ротационная стабильность

Для цитирования: Вариабельность антеролатеральной связки на МРТ – отсутствие стандартизации исследований или варианты анатомии? / А. А. Коструб [и др.] // Вес. Нац. акад. навук Беларусі. Сер. мед. навук. – 2021. – Т. 18, № 1. – С. 58–68 (*на англ.*). https://doi.org/10.29235/1814-6023-2021-18-1-58-68

by the anatomical study the existence of ALL as a separate structure, described the structure of the anterolateral capsule of two layers, which were found to be fused into one contiguous layer anterior to the fibular collateral ligament. According to E. Herbst et al. (2017) in the area where the two layers of the joint capsule merged, a capsular thickening, or mid-third capsular ligament (described before by Hughston et al.) was present in 35 % of the specimens. Furthermore, the coronary ligaments, consisting of meniscofemoral and meniscotibial ligaments, were observed in all specimens. It seems that the inconsistency of the two-layer structure of ALL on MRI can be explained by the fact that these two layers (described above as layers of the anterolateral capsule) are merged in individual patients at different levels. But at another level we see meniscofemoral and meniscotibial ligaments, which are also perceived by some scientists as elements of the ALL. Thus, in fact, we can expect to see the following picture (Fig. 1) of the structure of ALL with different variations in the localization of the stratification zone, which depends on the anatomical features as well as the presence of synovitis in this area, which improves the separation of the ALL layers and of the ALL and surrounding structures (Fig. 2) due to their better visualization because of the presence of liquid with a high signal intensity between the layers.

Another question arose while analyzing ALL on MRI – what exactly to consider to be the two-layer structure of ALL? ALL almost always looks two-layered in the zones of attachment of meniscotibial and meniscofemoral portions to tibial and femoral portions. But it can go as a single sheet a little bit further (Fig. 3).

A *B*

Fig. 1. Schematic representation of ALL on coronal MRI section: A – the more anterior section, immediately behind the attachment of the iliotibial tract, *B* – the more posterior section, closer to the fibular collateral ligament (the figure shows the most complete image of the ALL, which in practice usually looks very variable and often not with all the elements; the bifurcation of the layers may be more or less noticeable). ALL – anterolateral ligament, ALL-F – femoral portion of the ALL, ALL-F-S – superficial layer of the femoral portion of the ALL, ALL-F-D – deep layer of the femoral portion of the ALL, ALL-T – tibial portion of the ALL, ALL-T-S – superficial layer of the tibial portion of the ALL, ALL-S – superficial layer of the ALL, ALL-MT – meniscotibial portion of the ALL, ALL-MF – meniscofemoral portion of the ALL, FCL – fibular collateral ligament, ITB – iliotibial band, V – vessels between the ALL and lateral meniscus (arteria et vena inferiores laterales genus), LM – lateral meniscus, F – fibula, x – the proximal fibers merging zone of the superficial layer of the ALL femoral portion and the fibular collateral ligament, o – the merging zone of the superficial and deep layers of the femoral portion of the ALL, * – the merging zone of the superficial and deep layers of the tibial portion of the ALL

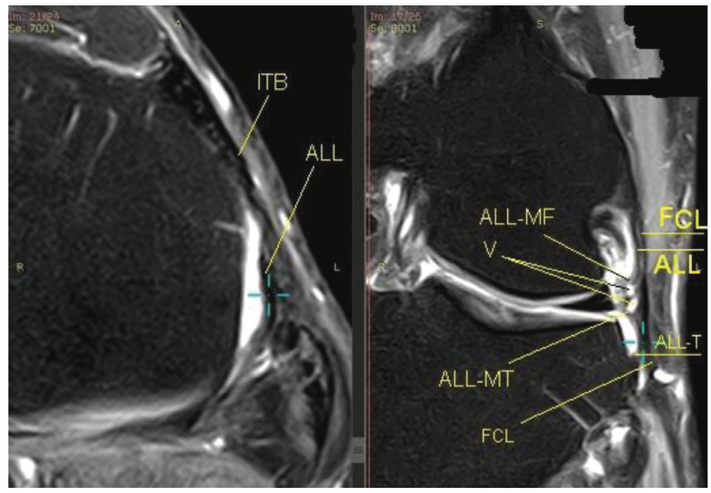

A *B*

Fig. 2. MRI imaging of the ALL in the 60-year-old patient with gouty synovitis: A – a strong tibial portion of the ALL and the ALL attachment site are well visualized, *B* – all portions of the ALL are well visualized (ALL is visualized deeper than the fibular collateral ligament, though according to a number of studies, the ALL fibers in the proximal parts should be superficial or merged with the fibular collateral ligament). Designations as in Fig. 1

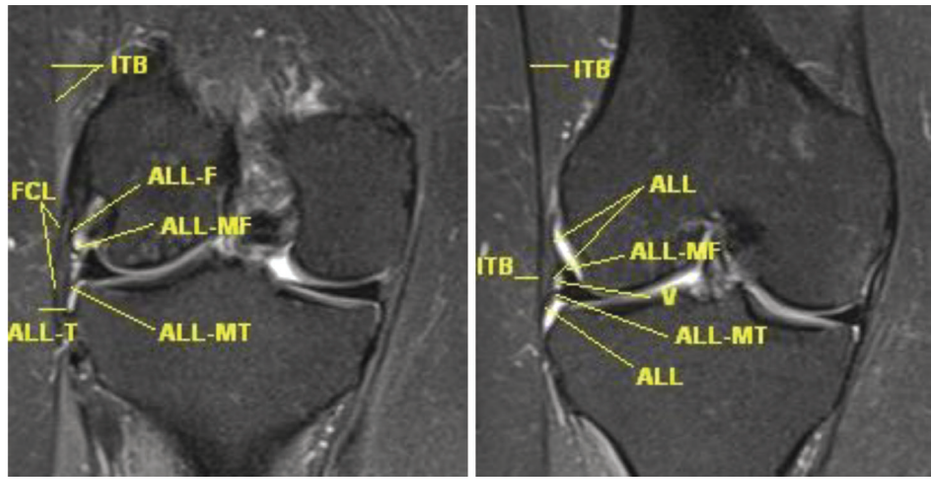

A *B*

Fig. 3. Coronal MRI sections of the knee joint with the ALL in a patient with partial anterior cruciate ligament injury: A – only one layer of the ALL is displayed, *B* – the more anterior coronal section (the single-layer structure of the ALL is visualized; in both images arteria et vena inferiores laterales genus are visualized between the ALL and the lateral meniscus). Designations as in Fig. 1

Sometimes we see a two-layer structure of ALL on MRI (Fig. 4–6). But we cannot always say for sure whether it is always really two layers of ALL or ALL with a joint capsule. Especially often such a recess which rather resembles the course of the capsule is observed on oblique coronal sections in MRI examination of ACL (Fig. 7). Sometimes we better see the femoral portion of the ALL on oblique coronal images made for ACL injury diagnostics (Fig. 7), sometimes – tibial (Fig. 8). Unfortunately, the assumption that ALL can be consistently better visualized on such MRI series has not been confirmed, as the angle of inclination of the sections corresponds to the angle of inclination of ACL, which is significantly greater than 20° inclination of ALL. We can assume that we` will be able to better trace the ALL throughout by using oblique coronal sections with an angle of 20°.

In some patients it was difficult to separate the ALL in certain areas from the lateral collateral ligament, iliotibial tract, or joint capsule, so certain portions of ALL looked quite contradictory on MRI. However, other parts of ALL could be well visualized and looked like a separate anatomical structure with typical fixation points and a course not typical for other anatomical entities. The relationship of certain ALL

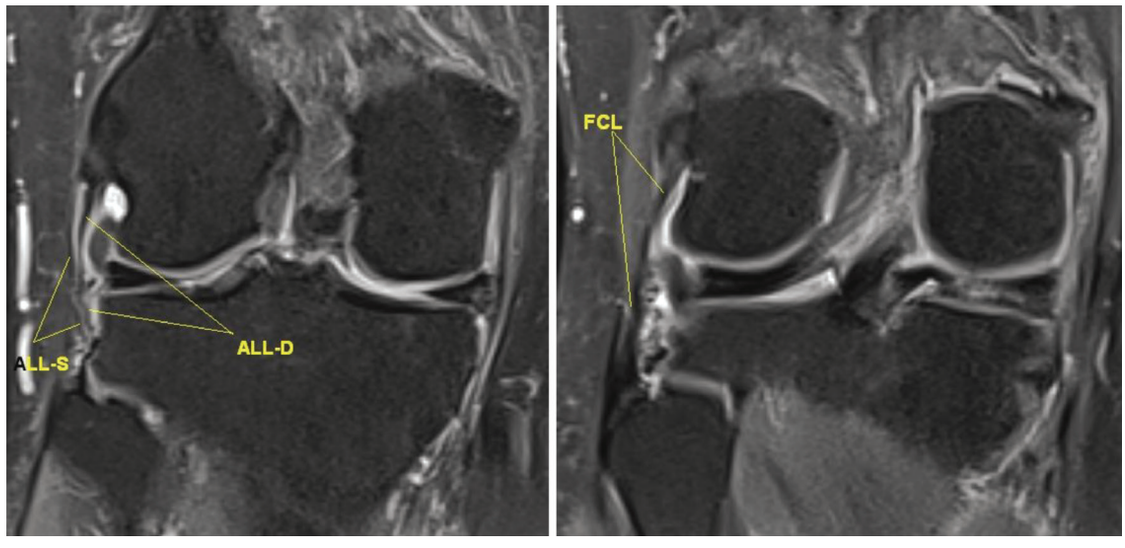

A *B*

Fig. 4. Two-layer structure of the ALL on MRI images (1.5 Tesla MRI scanner) in the 68-year-old patient with degenerative damage to the medial meniscus (A – ALL is clearly traced as separate two layers throughout with wavy appearence in the distal (tibial) segments in both its sheets; *B* – fibular collateral ligament of the same patient, to illustrate the direction of its course separately from ALL). ALL-D – deep layer of the ALL, ALL-S – superficial layer of the ALL, FCL – fibular collateral ligament

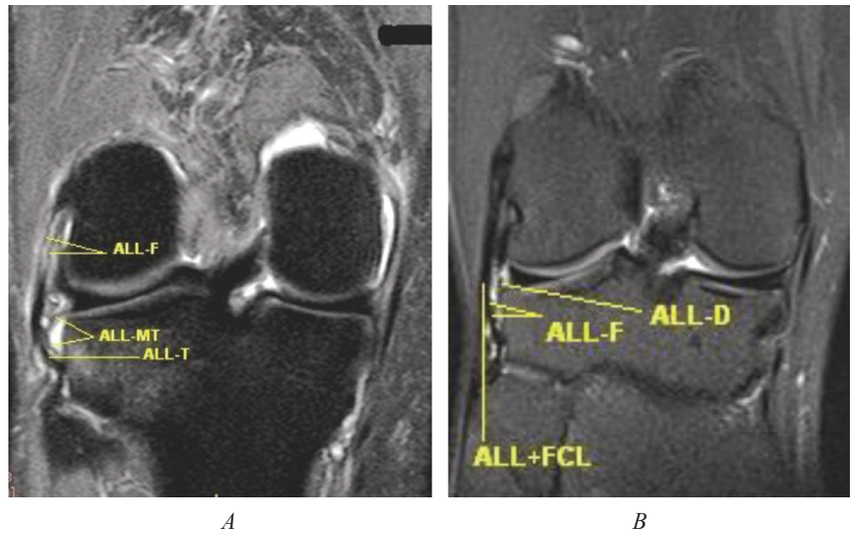

A *B*

Fig. 5. Two-layer ALL in a patient with partial anterior cruciate ligament injury: A – acute period after injury (we see the wavy appearance of the superficial and deep layers of the femoral portion of the ALL (ALL-F); some studies have described this as a sign of ALL damage); *B* – the same knee one year after the injury (this time we see the wavy course of the deep portion of the ALL (ALL-D) in another location). Designations are as in Fig. 1

anatomical variants with other anatomical or clinical parameters as well as distinctive features of ALL in children and adolescents have not been identified so far.

We have not been able to confirm the assumption that we can more clearly or more often separate the layers of ALL or see it separately from the joint capsule on MRI in children and adolescents, while degenerative changes in older age can complicate the visualization of fine structures. C. P. Helito et al. (2018) [16] also wrote about the worse imaging of ALL on MRI in children. Visualization of superficial and deep sheets of ALL according to the MRI images analyzed by us thus far did not depend on the age of the patient. Fig. 9 shows the ALL in a 14-year-old girl with a rupture of the lateral discoid meniscus, which occurred without trauma. This case demonstrates the lack of advantages of a young age for the quality of ALL imaging.

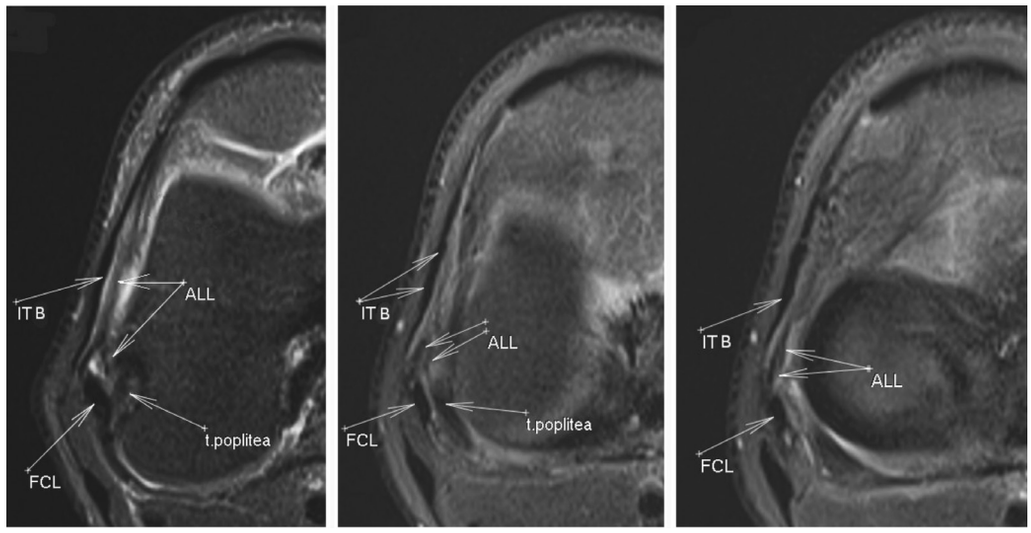

A *B* *C*

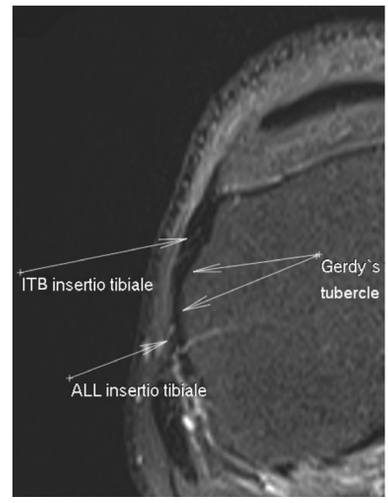

D

Fig. 6. Axial sections of the lateral part of the knee joint on a 1.5 Tesla MRI scanner: A, *B*, *C* – the two-layer structure of the ALL; *D* – the area of attachment of the ALL to the tibia. Designations are as in Fig. 1

Such variability of MRI imaging of the normal ALL may explain the diverse and sometimes contradictory anatomical findings. The following illustrations will show the variability of the MRI pattern of the ALL.

The question of what exactly we see on MRI only seems simple at first glance. The new articles constantly appear describing the visualization of relatively thin structures on MRI, which we have seen before, but not always associated with them, or found not constantly, or have not paid attention to. Thus, Batty L. and others published an article on MRI in 2019 with a picture of Kaplan fibers, which we, of course, have seen before, but were not always sure that we saw exactly them [18]. Participants of the ALL consensus compared this situation with a similar situation with the medial patellofemoral ligament. Several anatomical studies did not identify it at all in the early stages of studying its anatomy and its role in the stability of the patella [19]. However, in many MRI images the ALL looks so clear (Fig. 12) with typical areas of attachment to the bone that it is difficult to explain it by any other structure.

Perhaps improving the quality of MRI will increase resolution and will allow us seing ALL more clearly. Undoubtedly, depending on the characteristics of the MRI scanner (magnitude of the magnetic field, number of channels, etc.) and the study protocol, we have more or less chance to see the structure of the ALL. It is true to say that we rarely visualize ALL in detail with low-field MRI tomographs and with large interslice intervals. However, with an adequate study protocol, the frequency of ALL identifying with MRI even on low-field tomographs is not much lower than on higher-quality tomographs. Of course, the quality of imaging is inferior to more powerful devices and it is more difficult to assess

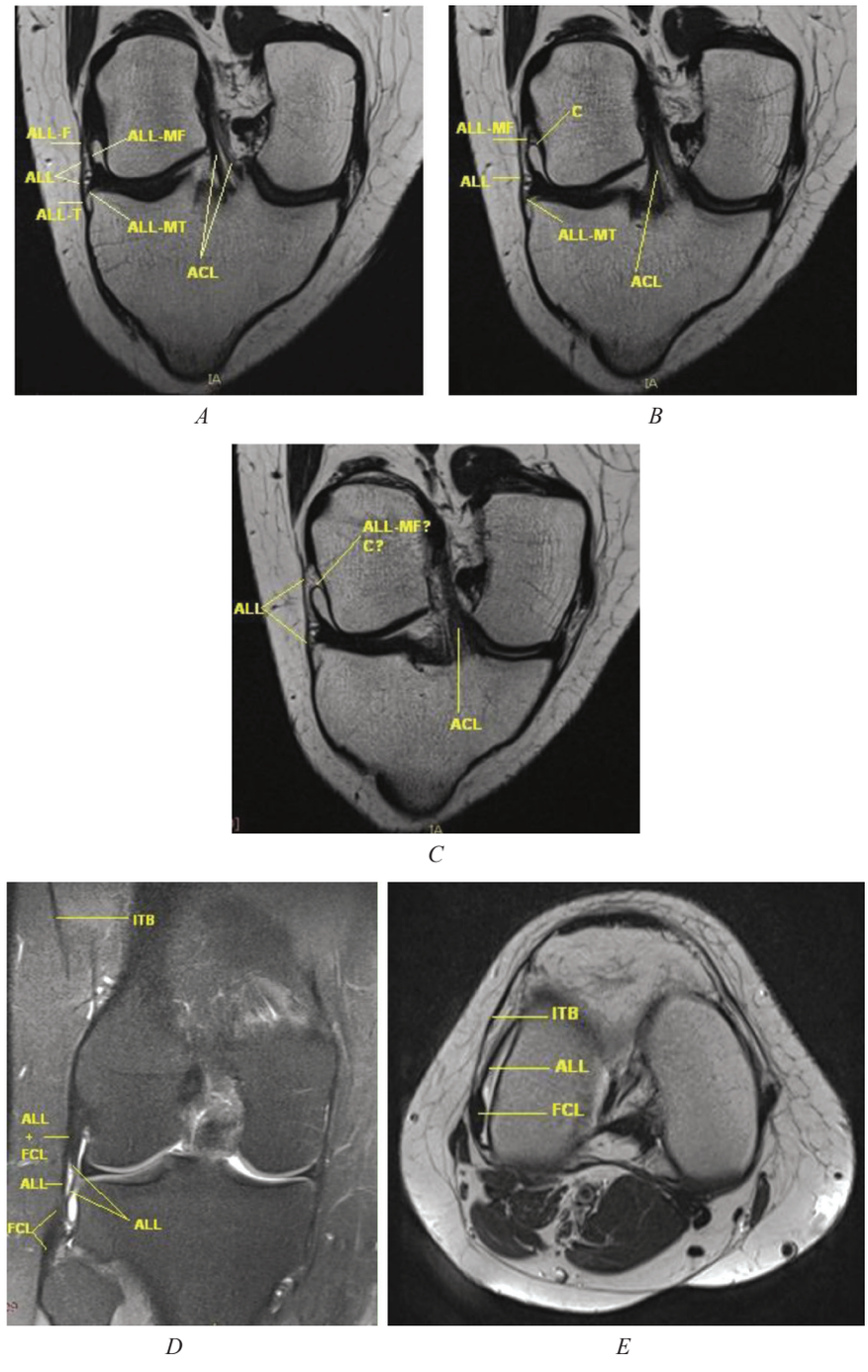

Fig. 7. MRI of a 28-year-old woman's knee joint with synovitis in the lateral parts and a well-defined ALL (1.5 Tesla MRI scanner)*: A*, *B*, *C* – oblique coronal sections corresponding to the direction of the ACL fibers (In some cases, the inclination angle of such sections better corresponds to the angle of inclination of the ALL. So, sometimes they allow visualizing ALL better than in standard coronal sections. If in Fig. A we think that we can confidently see the two-layer structure of ALL, and in Fig. *B* we even separate the meniscofemoral portion and the joint capsule, then in Fig. *C* the question arises – what exactly do we see – the meniscofemoral portion of ALL or joint capsule (ALL-MF vs C)? The intensity of the structure suggests that this is the ligament or at least thickened to withstand loads fibrous capsule of the joint. However, its recess as in Fig. *C* resembles rather the recess of the joint capsule. This form we observe in oblique coronal sections quite often. Sometimes we see a much tighter structure attached to the femoral condyle as in Fig. *B* (ALL-MF), which we consider to be a portion of ALL. But how to interpret such a recess of the capsule, and whether it can be stretched during flexion and internal rotation? The question remains open); *D* – we also see a two-layer structure of the ALL on the coronal section, but proximal fibers of its superficial femoral portion are merged with the fibular collateral ligament (ALL + FCL); *E* – axial sections of this patient. It is more difficult to see the superficial and deep layers of ALL simultaneously in one image possibly due to the merging of the fibers of its femoral portion with the fibular collateral ligament *C* – joint capsule, the rest designations are as in Fig. 1

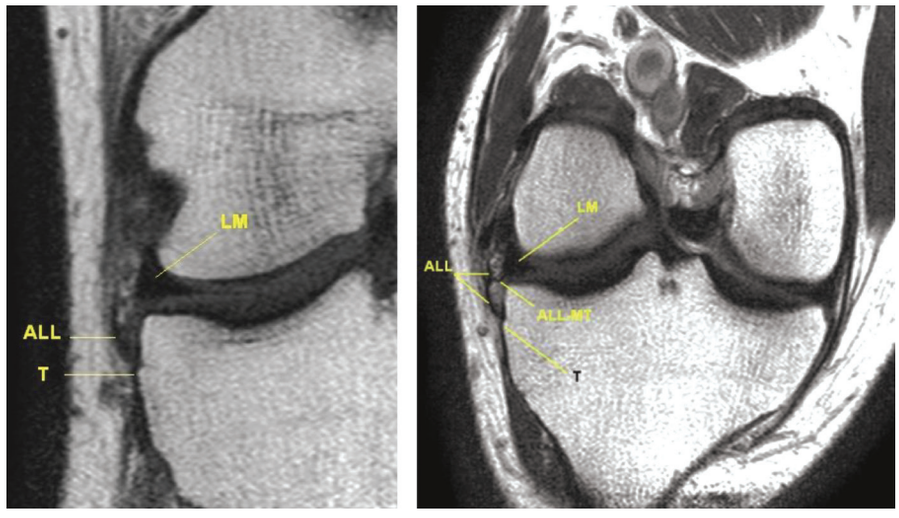

A *B*

Fig. 8. Coronal (A) and oblique coronal (*B*) section of a healthy knee joint according to the direction of the ACL fibers with visualization of ALL (MRI scanner 1.5 Tesla). T – tibia, the rest designations are as in Fig. 1

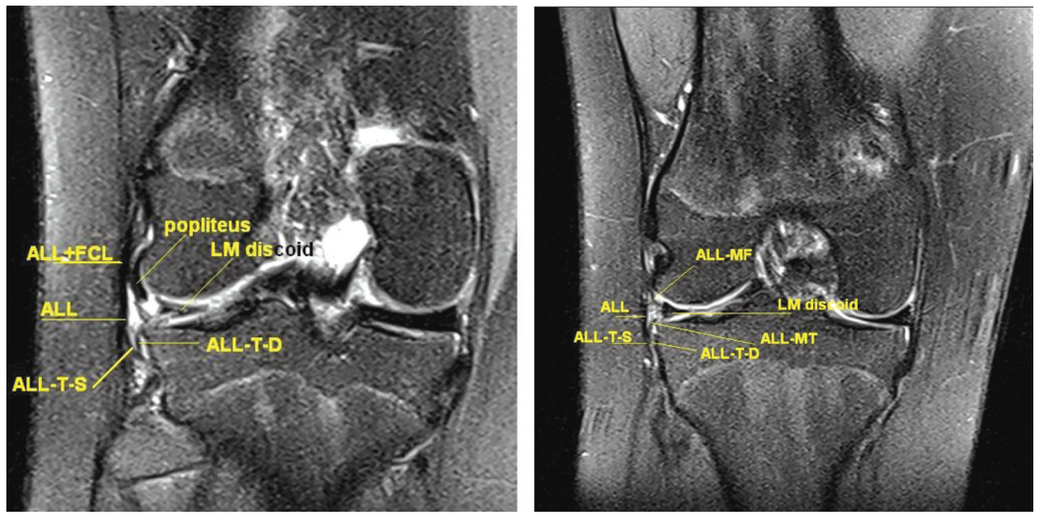

A *B*

Fig. 9. ALL in a 14-year-old girl with a non-traumatic rupture of the lateral discoid meniscus: *A* – more anterior coronal section, *B* – more posterior coronal section (Rather poor and fragmental visualization of ALL in spite of local synovitis, small interslice interval and high quality 1,5 Tesla MRI scanner. The continuity of ALL is rather questionable in this case. But there was no history of trauma)

its integrity or injury signs, certain portions are less confidently identified, but the general features and the presence of ALL can usually be assessed by such MRI.

The wavy appearance of certain portions of ALL was observed by us in some normal knee joints without a history of injuries (see Fig. 4) and in some knee joints with a minor injury but without other signs of possible ALL rupture (Fig. 10). We suggest that this may be due to a decrease in tension of ALL with full extension and neutral rotation of the lower leg. However, it can also be a symptom of ALL injury [17]. Of course, if its injury is suspected as in Fig. 5 and Fig. 11, this symptom should be taken into account, but not relied on as the only diagnostic criterion. And perhaps the injured knee joint should be compared with a healthy contralateral one.

Various scientists report MRI images of injured ALL in their publications. There are only few questions about the Segond fracture. But not all the images of the ALL rupture presented in these publications [20, 21] can be interpreted unambiguously. Given that ALL according to operative explorations in most cases (more than 57 %) is torn not transversely and without a Segond fracture, but with rupture of fibers

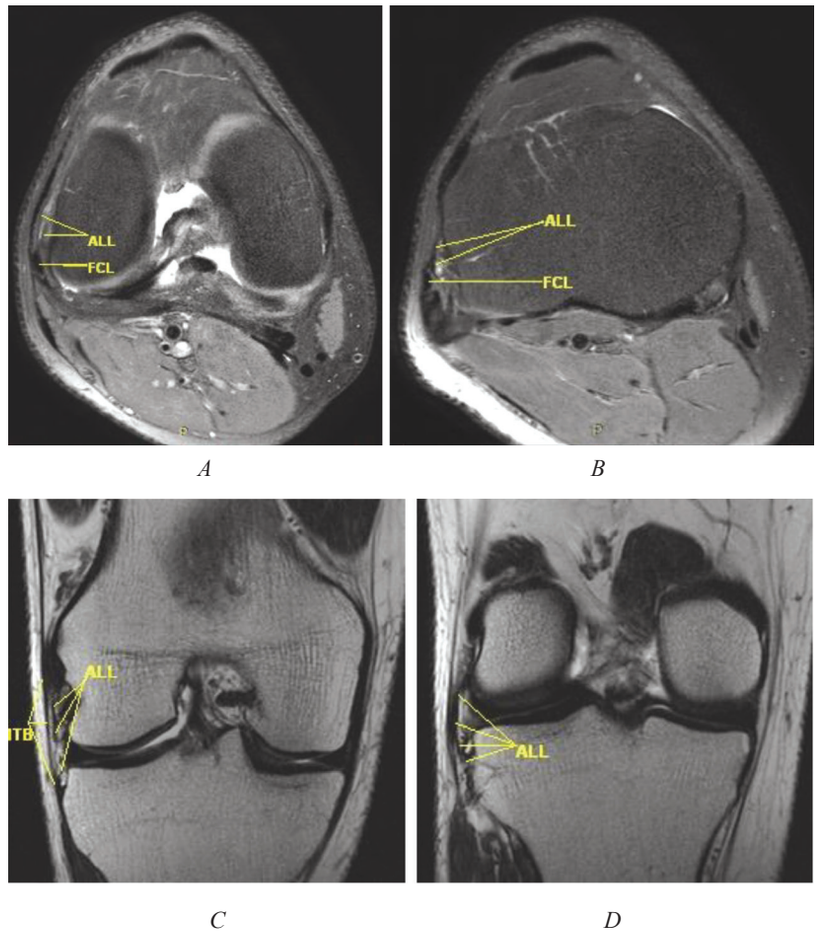

Fig. 10. MRI on a Philips Achieva 3.0 Tesla scanner of a 40-year-old man's knee with partial ACL injury: A, *B* – axial sections; *C*, *D* – coronal sections (ALL is relatively thin, but its two-layer structure is well traced on the axial section (A). On coronal section (*C*), the ALL appears somewhat wavy, which could potentially be a sign of at least partial damage, but given the absence of local edema and significant inflammatory changes and MRI conducted in the acute period, we can assume this as a variant of the normal). Designations are as in Fig. 1

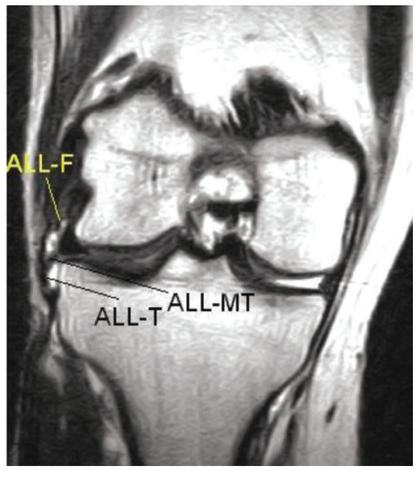

Fig. 11. Highly possible rupture of the ALL in the knee joint with synovitis in a patient with acute ACL rupture (The wavy fibers of the femoral portion of the ALL (ALL-F) may be a sign of its injury. However, as we see in previous series of images, such waviness is often visualized in healthy knee joints. Therefore, we can't claim that the ALL is damaged in this image. But all considered ALL is much like to be ruptured). Designations are as in Fig. 1

Fig. 12. The thick ALL in patient with medial knee osteoarthritis and varus deformity (It can be assumed that such ALL hypertrophy is caused by chronic overload of the lateral structures of the joint or by chronic inflammatory process in the knee joint. Or we may consider such a thick ALL as an anatomical variant)

and lateral capsule of the joint at different levels [19], we should expect in most cases similar indirect signs of rupture on MRI in the form of edema, etc. Unfortunately, these indirect signs are difficult to evaluate definitively. The example of very possible ALL rupture is shown in Fig. 11 and a complete absence of ALL after the recurrent complete knee dislocation in Fig. 13.

A limitation of the study is the analysis of ALL on MRI images obtained from the different MRI scanners according to different study protocols. This does not allow standardizing patients, and, therefore, obtaining reliable results of the sensitivity of the method on a particular tomograph and with a certain protocol, but it allows analyzing the reasons of different results of MRI and anatomical studies as well as understanding their causes – differences in equipment, study protocols or anatomical differences among patients.

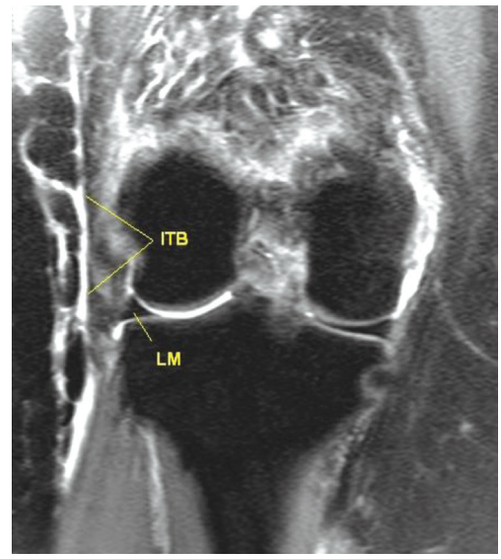

Fig. 13. Complete absence of ALL after the recurrent complete knee dislocation. Designations are as in Fig. 1

Conclusion. The ALL is a separate anatomical element of the knee joint that has a variable, but in most cases two-layered, anatomical structure and can be detected on MRI in at least 88 % of cases. Improving the quality of MRI scanners and study protocols with a decrease in the interslice intervals in the frontal plane can increase the frequency and quality of imaging of the ALL. Axial sections help to identify ALL in complex cases and allow analyzing its anatomy but adding little to the diagnosis of the ALL injury.

Conflict of interests. The authors declare no conflict of interests.

References

1. Claes S., Vereecke E., Maes M., Victor J., Verdonk P., Bellemans J. Anatomy of the anterolateral ligament of the knee. *Journal of Anatomy*, 2013, vol. 223, no. 4, pp. 321–328. https://doi.org/10.1111/joa.12087

2. Vieira E. L. C., Vieira E. A., da Silva R. T., dos Santos Berlfein P. A., Abdalla R. J., Cohen M. An anatomic study of the iliotibial tract. *Arthroscopy: The Journal of Arthroscopic and Related Surgery*, 2007, vol. 23, no. 3, pp. 269–274. https://doi.org/10.1016/j.arthro.2006.11.019

3. Lee D. W., Lee J. H., Kim J. N., Moon S. G., Kim N. R., Kim D. H., Kim J. G. Evaluation of anterolateral ligament injuries and concomitant lesions on magnetic resonance imaging after acute anterior cruciate ligament rupture. *Arthroscopy: The Journal of Arthroscopic and Related Surgery*, 2018, vol. 34, no. 8, pp. 2398–2406. https://doi.org/10.1016/j.arthro.2018.02.048

4. Fardin P. B. A., de Fúcio Lizardo J. H., da Silva Baptista J. Study of the Anterolateral Ligament of the knee in formalin-embedded cadavers. *Acta Ortopédica Brasileira*, 2017, vol. 25, no. 2, pp. 89–92. https://doi.org/10.1590/1413-785220172502162204

5. Brockmeyer M., Orth P., Höfer D., Seil R., Paulsen F., Menger M.D., Kohn D., Tschernig T. The anatomy of the anterolateral structures of the knee – a histologic and macroscopic approach. *Knee*, 2019, vol. 26, no. 3, pp. 636–646. https://doi.org/10.1016/j.knee.2019.02.017

6. Vincent J.-P., Magnussen R. A., Gezmez F., Uguen A., Jacobi M., Weppe F. [et al.]. The anterolateral ligament of the human knee: an anatomic and histologic study. *Knee Surgery, Sports Traumatology, Arthroscopy*, 2012, vol. 20, no. 1, pp. 147–152. https://doi.org/10.1007/s00167-011-1580-3

7. Helito C. P., Demange M. K., Bonadio M. B., Tírico L. E., Gobbi R. G., Pécora J. R., Camanho G. L. Anatomy and histology of the knee anterolateral ligament. *Orthopaedic Journal of Sports Medicine*, 2013, vol. 1, no. 7, art. ID 2325967113513546. https://doi.org/10.1177/2325967113513546

8. Caterine S., Litchfield R., Johnson M., Chronik B., Getgood A. A cadaveric study of the anterolateral ligament: re-introducing the lateral capsular ligament. *Knee Surgery, Sports Traumatology, Arthroscopy*, 2015, vol. 23, no. 11, pp. 3186–3195. https://doi.org/10.1007/s00167-014-3117-z

9. Kennedy M. I., Claes S., Fuso F. A., Williams B. T., Goldsmith M. T., Turnbull T. L., Wijdicks C. A., LaPrade R. F. The anterolateral ligament: an anatomic, radiographic, and biomechanical analysis. *American Journal of Sports Medicine*, 2015, vol. 43, no. 7, pp. 1606–1615. https://doi.org/10.1177/0363546515578253

10. Faruch B. M., Cavaignac E., Wytrykowski K., Constans O., Lapègue F., Chiavassa G. H., Larbi A., Sans N. Anterolateral ligament injuries in knees with an anterior cruciate ligament tear: contribution of ultrasonography and MRI. *European Radiology*, 2018, vol. 28, no. 1, pp. 58–65. https://doi.org/10.1007/s00330-017-4955-0

11. Cho H. J., Kwak D. S. Anatomical consideration of the anterolateral ligament of the knee. *BioMed Research International*, 2019, vol. 2019, art. ID: 5740473. https://doi.org/10.1155/2019/5740473

12. Nasu H., Nimura A., Yamaguchi K., Akita K. Morphology of the anterolateral ligament: a complex of fibrous tissues spread to the anterolateral aspect of the knee joint. *Anatomical Science International*, 2020, vol. 9, no. 4, pp. 470–477. https://doi.org/10.1007/s12565-020-00543-1 [Epub ahead of print].

13. Herbst E., Albers M., Burnham J.M., Fu F. H., Musahl V. The anterolateral complex of the knee. *Orthopaedic Journal of Sports Medicine*, 2017, vol. 5, no. 10, art. ID 2325967117730805. https://doi.org/10.1177/2325967117730805

14. Fu F., Kowalczuk M. (ed.). *Controversies of the anterolateral complex of the knee, an issue of clinics in sports medicine. Vol. 37-1.* Philadelphia, Elsevier, 2017. 160 p.

15. Helito C. P., do Amaral C. Jr., Nakamichi Y. D., Gobbi R. G., Bonadio M. B., Natalino R. J., Pécora J. R., Cardoso T. P., Camanho G. L., Demange M. K. Why do authors differ with regard to the femoral and meniscal anatomic parameters of the knee anterolateral ligament? *Orthopaedic Journal of Sports Medicine*, 2016, vol. 4, no. 12, art. ID 2325967116675604. https://doi.org/10.1177/2325967116675604

16. Helito C. P., Helito P. V. P., Leão R. V., Louza I. C. F., Bordalo-Rodrigues M., Cerri G. G. Magnetic resonance imaging assessment of the normal knee anterolateral ligament in children and adolescents. *Skeletal Radiology*, 2018, vol. 47, no. 9, pp. 1263–1268. https://doi.org/10.1007/s00256-018-2933-5

17. Devitt B. M., O'Sullivan R., Feller J. A., Lash N., Porter T. J., Webster K. E., Whitehead T. S. MRI is not reliable in diagnosing of concomitant anterolateral ligament and anterior cruciate ligament injuries of the knee. *Knee Surgery, Sports Traumatology, Arthroscopy*, 2017, vol. 25, no. 4, pp. 1345–1351. https://doi.org/10.1007/s00167-017-4538-2

18. Batty L., Murgier J., O'Sullivan R., Webster K. E., Feller J. A., Devitt B. M. The kaplan fibers of the iliotibial band can be identified on routine knee magnetic resonance imaging. *American Journal of Sports Medicine*, 2019, vol. 47, no. 12, pp. 2895–2903. https://doi.org/10.1177/0363546519868219

19. Sonnery-Cottet B., Daggett M., Fayard J. M., Ferretti A., Helito C. P., Lind M. [et al.]. Anterolateral Ligament Expert Group consensus paper on the management of internal rotation and instability of the anterior cruciate ligament – deficient knee. *Journal of Orthopaedics and Traumatology: Official Journal of the Italian Society of Orthopaedics and Traumatology*, 2017, vol. 18, no. 2, pp. 91–106. https://doi.org/10.1007/s10195-017-0449-8

20. Bonasia D. E., D'Amelio A., Pellegrino P., Rosso F., Rossi R. Anterolateral ligament of the knee: back to the future in anterior cruciate ligament reconstruction. *Orthopedic Reviews (Pavia)*, 2015, vol. 7, no. 2, article ID. 5773. https://doi.org/10.4081/or.2015.5773

21. Hegaze A., Khashoggi K., Alsayyad M., Hafiz R., Alqrache A., Mustafa H. N. Correlation between ACL injury and involvement of the anterolateral ligament: a retrospective study. *Current Orthopaedic Practice*, 2020, vol. 31, no. 1, pp. 23–29. https://doi.org/10.1097/BCO.0000000000000834

Information about the authors

Oleksandr O. Kostrub – D. Sc. (Med.), Professor, Head of the Department. Institute of Traumatology and Orthopedics of the National Academy of Medical Sciences of Ukraine (27, Bulvarno-Kudriavska Str., 01601, Kyiv, Ukraine). E-mail: akostrub@ukr.net https://orcid.org/0000-0001-7925-9362

Viktor V. Kotiuk – Ph. D. (Med.), Senior Researcher. Institute of Traumatology and Orthopedics of the National Academy of Medical Sciences of Ukraine (27, Bulvarno-Kudriavska Str., 01601, Kyiv, Ukraine). E-mail: kotyuk_v@,ukr.net https://orcid.org/0000-0001-8837-8603

Iurii V. Poliachenko – D. Sc. (Med.), Professor, Acting Director. Institute of Traumatology and Orthopedics of the National Academy of Medical Sciences of Ukraine (27, Bulvarno-Kudriavska Str., 01601, Kyiv, Ukraine). E-mail: poliach.yv@gmail.com https://orcid.org/0000-0003-1814-4240

Mikhail A. Gerasimenko – D. Sc. (Med.), Professor, Director. Republican Scientific-Practical Center of Traumatology and Orthopedics (60/4, Kizhevatov Str., 220024, Minsk, Republic of Belarus). E-mail: vbo@ortoped.by

Roman I. Blonskyi – D. Sc. (Med.), Leading Researcher. Institute of Traumatology and Orthopedics of the National Academy of Medical Sciences of Ukraine (27, Bulvarno-Kudriavska Str., 01601, Kyiv, Ukraine). E-mail: drblonskiy@ukr.net https://orcid.org/0000-0003-2310-6345

Ivan A. Zasadnyuk – Ph. D. (Med.), Researcher. Institute of Traumatology and Orthopedics of the National Academy of Medical Sciences of Ukraine (27, Bulvarno-Kudriavska Str., 01601, Kyiv, Ukraine). E-mail: zasadnyuk@ukr.net https://orcid.org/0000-0002-1099-4454

Информация об авторах

Коструб Александр Алексеевич – д-р мед. наук, профессор, заведующий отделом. Институт травматологии и ортопедии НАМН Украины (ул. Бульварно-Кудрявская, 27, 01601, г. Киев, Украина). E-mail: akostrub@ukr.net, https://orcid.org/0000-0001-7925-9362

Котюк Виктор Владимирович – канд. мед. наук, ст. науч. сотрудник. Институт травматологии и ортопедии НАМН Украины (ул. Бульварно-Кудрявская, 27, 01601, г. Киев, Украина). E-mail: kotyuk_v@ukr.net https://orcid.org/0000-0001-8837-8603

Поляченко Юрий Володимирович – д-р мед. наук, профессор, и. о. директора. Институт травматологии и ортопедии НАМН Украины (ул. Бульварно-Кудрявская, 27, 01601, г. Киев, Украина). E-mail: poliach.yv@gmail.com https://orcid.org/0000-0003-1814-4240

Герасименко Михаил Александрович – д-р мед. наук, профессор, директор. Республиканский научно-практический центр травматологии и ортопедии (ул. Кижеватова, 60/4, 220024, г. Минск, Республика Беларусь). E-mail: vbo@ortoped.by

Блонский Роман Ивавнович – д-р мед. наук, вед. науч. сотрудник. Институт травматологии и ортопедии НАМН Украины (ул. Бульварно-Кудрявская, 27, 01601, г. Киев, Украина). E-mail: drblonskiy@ukr.net https://orcid.org/0000-0003-2310-6345

Засаднюк Иван Андреевич – канд. мед. наук, науч. сотрудник. Институт травматологии и ортопедии НАМН Украины (ул. Бульварно-Кудрявская, 27, 01601, г. Киев, Украина). E-mail: zasadnyuk@ukr.net https://orcid.org/0000-0002-1099-4454