ISSN 1814-6023 (Print)
ISSN 2524-2350 (Online)
UDC УДК 617.713:616-089.843-06
https://doi.org/10.29235/1814-6023-2020-17-2-170-177 Received 04.03.2020

Galina R. Semak

Belarusian State Medical University, Minsk, Republic of Belarus

CLINICAL STUDY OF THE EFFICACY OF LOW MOLECULAR WEIGHT SODIUM HYALURONATE IN COMPLEX TREATMENT OF CORNEAL GRAFT DISEASE

Abstract. The results of corneal graft disease treatment using low molecular weight sodium hyaluronate are presented.

The study included 19 patients (20 eyes) aged 24 to 87 years, who developed graft disease after keratoplasty because of chronic dystrophic corneal diseases. The severity of symptoms during treatment was evaluated weekly during the course of therapy using the OSDI (Ocular Surface Disease Index). To assess the dynamics of objective signs of Dry eye disease in dynamics, visometry, biomicroscopy, Schirmer's test and LIPCOF test were performed weekly before the next injection. A follow-up study was carried out a week after the last injection, with a 1-year dynamic observation following the treatment.

Changes in objective indicators of the anterior eye surface were characterized by positive dynamics during therapy. The Schirmer test ($p < 0.00001$) increased most rapidly and significantly with a lasting effect for a month, demonstrating a beneficial therapeutic effect on both the aqueous and mucinous layer of the tear film. A decrease in the OSDI index was noted after the first injection and decreased progressively during the course of treatment and after its completion up to one month after the last injection ($p < 0.00001$).

Keywords: hyaluronic acid, dry eye disease, regeneration, corneal dystrophy

For citation: Semak G. R. Clinical study of the efficacy of low molecular weight sodium hyaluronate in complex treatment of corneal graft disease. *Vestsi Natsyyanal'nai akademii navuk Belarusi. Seriya meditsinskikh navuk = Proceedings of the National Academy of Sciences of Belarus. Medical series*, 2020, vol. 17, no. 2, pp. 170–177. https://doi.org/10.29235/1814-6023-2020-17-2-170-177

Г. Р. Семак

Белорусский государственный университет, Минск, Республика Беларусь

КЛИНИЧЕСКОЕ ИССЛЕДОВАНИЕ ЭФФЕКТИВНОСТИ НИЗКОМОЛЕКУЛЯРНОГО ГИАЛУРОНАТА НАТРИЯ В КОМПЛЕКСНОМ ЛЕЧЕНИИ ЗАБОЛЕВАНИЙ ТРАНСПЛАНТАТА РОГОВИЦЫ

Аннотация. Представлены результаты лечения заболеваний трансплантата роговицы с использованием низкомолекулярного гиалуроната натрия.

В исследование было включено 19 пациентов (20 глаз) в возрасте от 24 до 87 лет, у которых после кератопластики развилась трансплантатная болезнь из-за хронических дистрофических заболеваний роговицы. Степень выраженности симптомов во время лечения оценивали еженедельно в течение курса терапии с использованием OSDI (индекса поверхностных заболеваний глаз). Для оценки объективных признаков болезни сухого глаза в динамике еженедельно перед следующей инъекцией выполняли визометрию, биомикроскопию, тест Ширмера и тест LIPCOF. Последующее исследование было проведено через неделю после последней инъекции. Динамическое наблюдение осуществляли в течение 1 года после лечения.

Изменения объективных показателей состояния передней поверхности глаза характеризовались положительной динамикой в процессе терапии. Наиболее быстро и значительно увеличивалась проба Ширмера ($p < 0{,}00001$) со стойким эффектом в течение месяца, что свидетельствует о благоприятном влиянии терапии как на водный, так и на муциновый слой слезной пленки. Снижение индекса OSDI было отмечено после первой инъекции и постепенно уменьшалось в процессе лечения и в течение месяца после последней инъекции ($p < 0{,}00001$).

Ключевые слова: гиалуроновая кислота, болезнь сухого глаза, регенерация, дистрофия роговицы

Для цитирования: Семак, Г. Р. Клиническое исследование эффективности низкомолекулярного гиалуроната натрия в комплексном лечении заболеваний трансплантата роговицы / Г. Р. Семак // Вес. Нац. акад. навук Беларусі. Сер. мед. навук. – 2020. – Т. 17, № 2. – С. 170–177. https://doi.org/10.29235/1814-6023-2020-17-2-170-177

Introduction. Chronic dystrophic corneal diseases (CDCD) present a group of diseases characterized by impaired metabolic processes, leading to a decrease in corneal transparency. Primary dystrophies are rare and genetically determined. Secondary ones result from various conditions: bacterial and viral keratitis, burn disease, endothelial-epithelial dystrophy and after surgical intervention while taking eye drops containing preservatives.

© Semak G. R., 2020

Keratoleukoma leads to impaired visual function. According to the World Health Organization, 5 % of the world's population suffers from corneal blindness. Other symptoms that reduce the quality of life of patients with CDCD (photophobia, lacrimation, foreign body sensation, rapid visual fatigability) are the manifestations of dry eye disease (DED).

To date, dry eye is considered to be a multifactorial disease of the ocular surface characterized by the impaired homeostasis of the tear film and accompanied by ocular symptoms, in which tear film instability and hyperosmolarity, ocular surface inflammation and damage as well as neurosensory abnormalities play an etiological role [1].

Creating sufficient hydration is not an easy task. During the progression of dystrophy and the formation of leukoma, various types of keratoplasty with the donor cornea are performed.

DED not only exacerbates the course of CDCD, but can also cause it. Efficient treatment of CDCD, including keratoplasty, is impossible without elimination of xeroses in pre- and postoperative period. The implantation of donor tissue is not possible without creating special conditions for the graft and restoring the quality of the tear film. Without effective elimination of DED manifestations, corneal graft results in transparent engraftment in only 30 % of cases. In 20 % of cases repeated keratoplasty is necessary [2].

After repeated keratoplasty, CDCD patients with advanced inflammation are in the "high risk group" and the probability of an adverse outcome of allotransplantation can reach 70 %. The treatment of coarse vascularized keratoleukoma of 3–5 categories, formed as a result of burns, is a special problem. In 18–79 % of such cases, keratoplasty results in the graft's opacity or rejection [3].

There is a need to develop a method that would not only maintain the necessary level of hydration, but also contribute to the activation of regenerative processes in the ocular surface tissue.

Hyaluronic acid (HA) is a natural component of the tear film mucin layer. As an osmoactive substance, it retains water molecules, eliminating the main link in the DED pathogenesis – tear hyperosmolarity. The HA pool in tissues is rather heterogeneous. The polysaccharide chain synthesized on the cell surface under certain conditions can be split by hyaluronidases into fragments of different molecular weight: high-molecular weight hyaluronan (HM-HA) – >1000 kDa, medium-molecular weight hyaluronan (MM-HA) – 250–1000, low-molecular weight hyaluronan (LM-HA) – 10–250 and oligo-GA – <10 kDa.

MM – medium-molecular hyaluronan 250–1000 kDa, and LM-HA low-molecular hyaluronan (10–250 kDa) are often detected as a polydisperse fraction of molecules with overlapping molecular weights. This average fraction accumulates as a result of the presence of different concentrations of hyaluronidases, active oxygen forms, as well as different activity of HA elimination mechanisms in the extracellular matrix. This fraction also includes synthesized HA molecules that have not yet reached high molecular weight. It is not surprising that MM- and LM-HA exhibit the properties of both HM and Oligo-HA. It is reported that MM-HA is able to induce mesenchymal cells differentiation (chondrocytes, keratinocytes, fibroblasts, including the induction of the growth factor expression; endotheliocytes), mediating a normal response to the damage [4, 5]. LM-HA accelerates wound healing by inducing of CD44 expression and accumulating type III collagen [6] (Fig. 1).

Interacting with neutrophil receptors, NM-GA induces their apoptosis, limiting the inflammatory response, since the infection is no longer present, but the characteristic inflammatory process causes dry eye, which should be managed.

Effect of exogenous HA on the extracellular matrix (ECM):

1. In a study of synovial envelope fibroblast culture, it was shown that exogenous HA of different molecular weight is capable of inducing endogenous HA synthesis [7].

2. *In vitro* experiments have demonstrated that exogenous HA can enhance the synthesis of chondroitin and keratan sulfate, which affect corneal transparency [8].

3. Exogenous HA of any molecular weight *in vitro* inhibits the expression of TNF-a (tumor necrosis factor α), IL1 (interleukin 1) and MMR3 (matrix metalloproteinase 3) [8].

4. HA of any molecular weight can inhibit the release of arachidonic acid and products of its transformation *in vitro* [9].

5. HA of any molecular weight can inhibit polymorphonuclear lymphocytes migration, as well as free radicals generated by them.

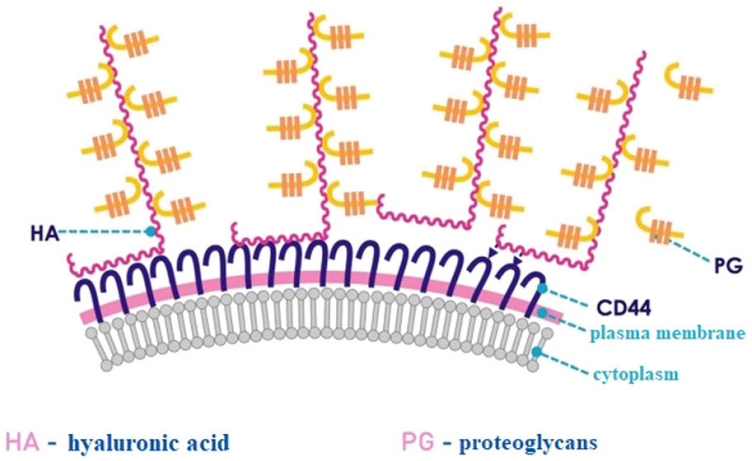

Fig. 1. Interaction between CD44 and hyaluronic acid molecules

Thus, the injection of exogenous HA in keratopathies may itself contribute to the regeneration and activation of metabolic processes in corneal tissues. The use of combined low and medium molecular weight HA fraction integrating the protective functions of high molecular weight hyaluronan and activating the effect of Oligo-GA on cells seems to be the most justified. An additional beneficial effect of the exogenous HA injection is activation of the endogenous HA synthesis, which in turn helps to restore homeostasis of the eye anterior segment for a long time after the course of treatment.

Drops with hyaluronic acid are effective at I–II degree DED. An example of medicine containing low-molecular hyaluronan [1] is Artelac Splash by Bausch and Lomb (Germany). It contains medium molecular weight hyaluronate (800 kDA molecule size and 0.24 % concentration), it is well tolerated by patients and contains no preservatives. Due to its high concentration, the preparation stays on the eye surface longer, allowing the effects of hyaluronate to be realized for a longer time.

In cases of the III–IV degree DED with a long course of the disease, the presence of complications (keratoleukoma, thinning, ectasias, corneal perforations), concomitant systemic and ophthalmologic pathology (especially, ophthalmic hypertension and glaucoma), the instillation therapy is not effective enough. Subconjunctival injection of low-molecular HA (allowed for injection) for treating graft disease with concomitant DED is seen as promising. The method of treating chronic degenerative-dystrophic diseases of soft tissues of the orbit and eye surface developed by us (Instruction on Application of the Ministry of Health of the Republic of Belarus no. 079-0519) has shown high efficacy for treating CDCD patients with advanced inflammation in endothelial-epithelial dystrophy and concomitant glaucoma.

The aim of the study is to establish the efficacy of low-molecular (500–700 kDa) hyaluronic acid in treating corneal graft disease.

Materials and research methods. 19 patients (20 eyes) aged 24 to 87 years, who underwent penetrating keratoplasty for various indications were included in the group “Graft disease”.

Before being included in this study, all patients were regularly monitored by an ophthalmologist and received suitable tear-substituting therapy using drops containing hyaluronic acid of different molecular weight in different concentrations.

The scope of ophthalmologic examinations included visometry, pneumotonometry, biomicroscopy, keratopachymetry, anterior segment OCT. DED diagnosing was obligatory, which included Schirmer test, the analysis of meibomium glands secretion and LIPCOF test.

Symptoms severity during treatment was assessed weekly using the OSDI (Ocular Surface Disease Index) test. The visometry, biomicroscopy, Schirmer test and LIPCOF test were conducted weekly before the next injection to assess DED objective features in dynamics. The follow-up study of a patient was conducted a week after the last injection. Upon completion of the therapy, patients were advised to continue using low or medium-molecular hyaluronate in the form of instillations. The dynamic observation was planned to be conducted in a year. Clinical and demographic characteristics of patients are given in Tab. 1.

Statistical analysis of the data was carried out using STATISTICA 10.0 software. The obtained results were statistically processed by calculating the median (Me), moda (Mo), interquartile range (25 % and 75 % percentiles) and 95 % confidence interval (MDIs), maximum and minimum values. The Shapiro–Wilk criterion was used to evaluate the distribution of the obtained data (statistical significance at $p < 0.05$). Comparison of independent samples by quantitative features was carried out using the dispersion analysis of non-parametric ANOVA data and the definition of Crucket Wallis criteria (-criterion) for 3 or more samples and Mann–Whitney criteria (*U*-criterion) for pairwise comparison of samples. The significance of differences for intragroup indicators was calculated using Wilcoxon criterion ( ) for paired comparisons and Friedman's rank dispersion analysis for comparing several dependent variables.

Results and its discussion. Corneal graft rejection, considering its localization in the corneal layers and the degree of severity, can be classified as follows: epithelial, chronic stromal, acute stromal, chronic endothelial, combined stromal-endothelial [2].

The study group included 15 cases with the graft disease and opaque engraftment following the first operation, 5 of which had acute epithelial rejection, 7 – chronic combined rejection, 3 – graft inflammation.

5 cases were also included in this group after primary keratoplasty with delayed epithelization. The course of therapy with hyaluronic acid injections was carried out after the operation if no epithelization for 3–5 days and graft edema were observed.

T a b l e 1. **Clinical and demographic characteristics of patients in the Graft Disease group (n = 20)**

Characteristics	Number of patients, Me [25 %–75 %]
Age, years	49.65 [29.5–62.0]
Symptoms duration, years	5.0 [4.0–7.0]
Duration of tear replacement therapy, years	5.0 [4.0–7.0]
Visual acuity	0.25 [0.35–0.2]
Photophobia, lacrimation, points	3.0 [3.0–3.0]
Intraocular pressure	Normal at palpation
Ocular surface disease index (OSDI), points	63.6 [43.75–77.0]

While taking sodium hyaluronate injections, in most cases a complete graft epithelialization was observed after the first injection with 100 % of defects epithelized after the second injection (Tab. 2, Fig. 2).

T a b l e 2. **The area of the graft deepithelialization site during therapy**

Observation number	Area of deepithelization site, mm^2, Me [25 %–75 %]
0 – before therapy	16.0 [9.0–30.25]
1 – after the 1st injection	0.0 [0.0–4.0]
2 – after the 2nd injection	0.0 [0.0–0.0]
Friedman analysis of variance	$X^2 = 8.37$, $p < 0.015$

Positive dynamics was also noted in young patients with a short period of DED according to LIPCOF test results. A decrease in the OSDI index has already been observed after the first injection ($p < 0.00001$) (Tab. 3).

T a b l e 3. **Change in the OSDI index during treatment in patients with delayed epithelization**

Observation number	OSDI index in patients with delayed epithelization, Me [25% –75%]
0 – before therapy	75.0 [75.0–100.0]
1 – after the 1st injection	30.0 [25.0–35.0]
2 – after the 2nd injection	25.0 [12.78–35.63]
Friedman analysis of variance	$X^2 = 22.72$, $p < 0.00001$

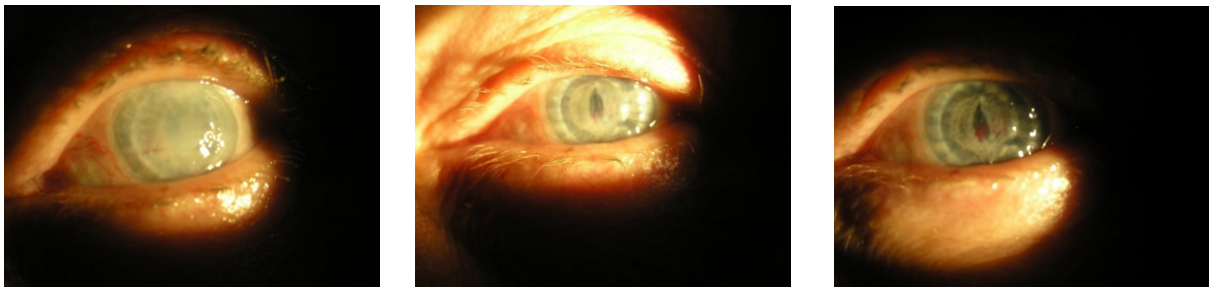

a *b* *c*

Fig. 7. Case 3-14, left eye: before treatment (*a*), after UPC (*b*), after sinustrabekulectomy (*c*)

out sinustrabulectomy to normalize IOP, to cancel hypotensive instillations with preservatives and to create better conditions for the eye surface restoration. After sinustrabulectomy, the corneal graft transparency increased a day later. A week later, we received a complete epithelization (Fig. 6).

Case 3-14. The repeated UPC was performed on the left eye after 1 % sodium hyaluronate no. 3 subconjunctival injections. In spite of the preoperative measures taken, slow epithelialization with the graft edema and increased IOP, while using beta-blocker instillations 2 times a day, were observed after UPC. In a month, a decision to perform a sinustrabekulectomy was made. The next day, the graft became more transparent, and after injecting of 1 % sodium hyaluronate, complete epithelization was achieved a week later (Fig. 7).

Such results prove the importance of normalizing intraocular pressure to maintain corneal transparency and improve the eye surface, especially in patients with corneal graft disease.

Conclusion. Patients with the corneal graft disease have increased risk of the graft rejection at repeated keratoplasty and therefore require special attention in the postoperative period. Complex treatment using weekly subconjunctival injection of low-molecular weight sodium hyaluronate (500–700 kDa) with the instillation of medicines containing low and medium-molecular weight hyaluronic acid allows not only to stop the manifestations of dry eye disease, but also has a positive effect on the graft's condition, potentially prolonging its lifetime.

Exclusion of instillations with benzalconium chloride is a prerequisite for the restoration of the corneal epithelium after surgical intervention, and reducing the pressure by means of surgery helps to avoid the use of local hypotensive medicines that produce toxic effects on the eye surface tissue.

Conflict of interests. The author declares no conflict of interest.

References

1. Nelson J. D., Craig J. P., Akpek E. K., Azar D. T., Belmonte C., Bron A. J. [et al.]. TFOS DEWS II Introduction. *The Ocular Surface*, 2017, vol. 15, no. 3, pp. 269–275. https://doi.org/10.1016/j.jtos.2017.05.005

2. Maeno A., Naor J., Lee H. M., Hunter W. S., Rootman D. S. Three decades of comeal transplantation: indications and patient characteristics. *Cornea*, 2000, vol. 19, no. 1, pp. 7–11. https://doi.org/10.1097/00003226-200001000-00002

3. Birnbaum F., Mayweg S., Reis A., Böhringer D., Seitz B., Engelmann K., Messmer E. M., Reinhard T. Mycophenolate mofetil (MMF) following penetrating high-risk keratoplasty: long-term results of a prospective, randomised, multicentre study. *Eye (Lond.)*, 2009, vol. 23, no. 11, pp. 2063–2070. https://doi.org/10.1038/eye.2008.402

4. Franzmann E. J., Schroeder G. L., Goodwin W. J., Weed D. T., Fisher P., Lokeshwar V. B. Expression of tumor markers hyaluronic acid and hyaluronidase (HYAL1) in head and neck tumors. *International Journal of Cancer*, 2003, vol. 106, no. 3, pp. 438–445. https://doi.org/10.1002/ijc.11252

5. Lokeshwar V. B., Cerwinka W. H., Isoyama T., Lokeshwar B. L. HYAL1 yaluronidase in prostate cancer: a tumor promoter and suppressor. *Cancer Research*, 2005, vol. 65, no. 17, pp. 7782–7789. https://doi.org/10.1158/0008-5472.can-05-1022

6. Simpson M. A., Lokeshwar V. B. Hyaluronan and hyaluronidase in genitourinarytumors. *Frontiers in Bioscience*, 2008, vol. 13, pp. 5664–5680. https://doi.org/10.2741/3108

7. Eissa S., Shehata H., Mansour A., Esmat M., El-Ahmady O. Detection of hyaluronidase RNA and activity in urine of schistosomal and non-schistosomal bladder cancer. *Medical Oncology*, 2012, vol. 29, no. 5, pp. 3345–3351. https://doi.org/10.1007/s12032-012-0295-8

8. Yoffou P. H., Edjekouane L., Meunier L., Tremblay A., Provencher D. M., MesMasson A.-M., Carmona E. Subtype specific elevated expression of hyaluronidase-1 (HYAL-1) in epithelial ovarian cancer. *PLoS ONE*, 2011, vol. 6, no. 6, p. e20705. https://doi.org/10.1371/journal.pone.0020705

9. Nykopp T. K., Rilla K., Tammi M. I., Tammi R. H., Sironen R., Hämäläinen K., Kosma V.-M., Heinonen S., Anttila M. Hyaluronan synthases (HAS1-3) and hyaluronidases (HYAL1-2) in the accumulation of hyaluronan in endometrioid endometrial carcinoma. *BMC Cancer*, 2010, vol. 10, no. 1, art. 512. https://doi.org/10.1186/1471-2407-10-512

10. Salzillo R., Schiraldi C., Corsuto L., D'Agostino A., Filosa R., de Rosa M., la Gatta A. Optimization of hyaluronan-based eye drop formulations. *Carbohydrate Polymers*, 2016, vol. 153, pp. 275–283. https://doi.org/10.1016/j.carbpol.2016.07.106

Information about the author

Galina R. Semak – Ph. D. (Med.), Assistant Professor. Belarusian State Medical University (83, Dzerzhinski Ave., 220116, Minsk, Republic of Belarus). E-mail: semakgalina@mail.ru

Информация об авторе

Семак Галина Романовна – канд. мед. наук, доцент. Белорусский государственный медицинский университет (пр. Дзержинского, 83, 220116, г. Минск, Республика Беларусь). E-mail: semakgalina@mail.ru