ISSN 1814-6023 (Print)
ISSN 2524-2350 (Online)

КЛІНІЧНАЯ І ЭКСПЕРЫМЕНТАЛЬНАЯ МЕДЫЦЫНА

CLINICAL AND EXPERIMENTAL MEDICINE

UDC 616-006:617.73
https://doi.org/10.29235/1814-6023-2026-23-4-271-278 Received 06.09.2026

Olga M. Holub[1], Larisa V. Naumenko[2], Sergey A. Krasny[2], Ekaterina P. Zhylyayeva[2], Galina A. Sushchenya[1], Alesya A. Evmenenko[2]

[1]Minsk Regional Children's Clinical Hospital, Borovlyany village, Minsk District, Republic of Belarus
[2]N. N. Alexandrov National Cancer Centre of Belarus, Lesnoy, Minsk District, Republic of Belarus

SECTORAL LASER COAGULATION OF THE RETINA WITH INTRAVITREAL GLUCOCORTICOID ADMINISTRATION IN THE TREATMENT OF CHOROIDAL MELANOMA

Abstract. Reducing the incidence and severity of radiation-associated complications in the treatment of choroidal melanoma (CM) remains a critical challenge in ocular oncology.

To evaluate the efficacy of sectoral laser coagulation (SLC) with glucocorticoid (GC) administration in patients with CM undergoing radiation therapy (RT).

This prospective randomized study included 60 patients with CM staged cT1–3N0M0 who received either brachytherapy (BT) or stereotactic radiotherapy (SRT). Patients in the main group underwent retinal SLC 3–4 weeks before RT. The onset and severity grade of radiation retinopathy were recorded. All patients received intravitreal GC (0.1 mL Kenalog).

In the control group, central retinal thickness (CRT) increased over the 6-month follow-up period: by 10 μm ($p < 0.001$). In the main group (with SLC), CRT remained stable: before RT – 285.0 [259.5–330.5] μm; at 1 month – 268.0 [238.3–306.3] μm ($p = 0.556$); at 3 months – 263.0 [230.3–285.5] μm ($p = 0.319$); and at 6 months – 266.0 [238.5–281.0] μm ($p = 0.387$). No significant increase in CRT was observed in the study group, indicating the absence of early signs of radiation maculopathy. At 6 months, CRT in the control group was 35 μm (13.2 %) higher than in the main group ($p = 0.004$).

Sectoral laser coagulation combined with intravitreal GC administration in patients with CM prior to radiation therapy demonstrated statistically significant efficacy in reducing CRT, thereby markedly decreasing the severity of radiation maculopathy.

Keywords: uveal melanoma, radiation therapy, radiation retinopathy, laser coagulation of the retina

For citation: Holub O. M., Naumenko L. V., Krasny S. A., Zhylyayeva E. P., Sushchenya G. A., Evmenenko A. A. Sectoral laser coagulation of the retina with intravitreal glucocorticoid administration in the treatment of choroidal melanoma. *Vestsi Natsyyanal'nai akademii navuk Belarusi. Seryya medytsynskikh navuk = Proceedings of the National Academy of Sciences of Belarus. Medical series*, 2026, vol. 23, no. 4, pp. 271–278 (in Russian). https://doi.org/10.29235/1814-6023-2026-23-4-271-278

О. М. Голуб[1], Л. В. Науменко[2], С. А. Красный[2], Е. П. Жиляева[2], Г. А. Сущеня[1], А. А. Евмененко[2]

[1]Минская областная детская клиническая больница, д. Боровляны, Минский район, Республика Беларусь
[2]Республиканский научно-практический центр онкологии и медицинской радиологии имени Н. Н. Александрова, аг. Лесной, Минский район, Республика Беларусь

СЕКТОРАЛЬНАЯ ЛАЗЕРКОАГУЛЯЦИЯ СЕТЧАТКИ С ИНТРАВИТРЕАЛЬНЫМ ВВЕДЕНИЕМ ГЛЮКОКОРТИКОИДОВ ПРИ ЛЕЧЕНИИ МЕЛАНОМЫ СОСУДИСТОЙ ОБОЛОЧКИ ГЛАЗА

Аннотация. Снижение количества и степени тяжести постлучевых осложнений при лечении меланомы хориоидеи (МХ) является актуальной задачей в онкоофтальмологии.

Цель работы – оценить эффективность секторальной лазерной коагуляции (СЛК) и применения глюкокортикоидов (ГКС) в лечении пациентов с использованием лучевой терапии (ЛТ) при МХ.

В проспективное рандомизированное исследование включены 60 пациентов с МХ с распространенностью опухоли cT1-3N0M0, которым проводилась брахитерапия (БТ) и стереотаксическая лучевая терапия (СЛТ). Пациентам

основной группы выполнялась СЛК сетчатки за 3–4 недели до лучевой терапии. Фиксировалось появление признаков постлучевой ретинопатии и степень ее тяжести. Пациентам всех групп вводился ГКС интравитреально (0,1 мл, кеналог).

Центральная толщина сетчатки (ЦТС) в контрольной группе в период наблюдения до 6 месяцев увеличилась на 10 мкм ($p < 0{,}001$). В основной группе не зафиксировано достоверного увеличения ЦТС, что указывает на отсутствие ранних признаков постлучевой макулопатии. У пациентов контрольной группы ЦТС через 6 месяцев была на 35 мкм (13,2 %) выше, чем в основной группе ($p = 0{,}004$).

СЛК с интравитреальным введением ГКС у пациентов с МХ перед проведением ЛТ достоверно показала свою эффективность по показателю ЦТС, значительно снижая степень постлучевой макулопатии.

Ключевые слова: увеальная меланома, лучевая терапия, постлучевая ретинопатия, лазеркоагуляция сетчатки

Для цитирования: Секторальная лазеркоагуляция сетчатки с интравитреальным введением глюкокортикоидов при лечении меланомы сосудистой оболочки глаза / О. М. Голуб, Л. В. Науменко, С. А. Красный [и др.] // Весці Нацыянальнай акадэміі навук Беларусі. Серыя медыцынскіх навук. – 2026. – Т. 23, № 4. – С. 271–278. https://doi.org/10.29235/1814-6023-2026-23-4-271-278

Introduction. Radiation therapy (RT) emerged in the mid-20th century as a therapeutic alternative to enucleation in patients with uveal melanoma (UM). Over recent decades, RT has undergone substantial changes, in terms of dose-delivery technologies with an expanded range of radiation sources. With the shift in treatment preferences for UM from primary enucleation toward eye-sparing RT, ocular oncologists have encountered an increased incidence of ocular complications including radiation retinopathy [1]. Therefore, the search for methods to reduce the frequency of radiation complications remains an important goal.

The aim of this study was to evaluate the efficacy of sectoral laser coagulation (SLC) combined with glucocorticoid (GC) administration in patients with choroidal melanoma (CM) undergoing RT.

Materials and methods. This prospective randomized study included 60 patients with CM staged cT1–3N0M0 who underwent either brachytherapy (BT) with a prescribed dose of 120–130 Gy to the tumor apex or single-fraction stereotactic radiotherapy (SRT) with a prescribed dose of 23–25–30 Gy to the tumor margin. The main group included 12 patients treated with BT and 18 treated with SRT, whereas the control group included 14 and 16 patients, respectively. Within- and between-group analyses of central retinal thickness (CRT) were performed. Patients in the main group underwent retinal SLC using a Quantel Medical VITRA 2 laser system (France) and a Goldmann three-mirror lens OG3M (Ocular, USA) 3–4 weeks before RT. All patients underwent optical coherence tomography (OCT) of the macular region and optic disc, as well as fundus photography, 3–4 weeks before RT and at 1, 3, and 6 months after RT. Additionally, a comparative analysis of complications was performed in all patients after SRT, stratified by whether SLC was performed. All patients received an intravitreal GC injection (0.1 mL Kenalog) via the pars plana.

The main and control groups were comparable with respect to sex, age, tumor stage, and baseline CRT values prior to RT, as shown in Table 1.

Table 1. **Distribution of patients in the main and control groups by sex, age, baseline CRT values before RT, and tumor stage**

Parameter		Main group	Control group
Number of patients, sex, n (male/female)		30 (9/21)	30 (10/20)
Age, years		64.5 [51.3–71.0]	68.0 [58.5–71.0]
CRT before RT, μm		257.0 [233.0–299.5]	256.0 [229.8–283.0]
Prevalence of tumor process (T)	T1	16	16
	T2	14	12
	T3		2

The onset and severity grade of radiation retinopathy were recorded according to the classification proposed by N. Horgan et al.: grade I – extrafoveal non-cystoid edema; grade II – extrafoveal cystoid edema; grade III – foveal non-cystoid edema; grade IV – mild to moderate foveal cystoid edema; and grade V – severe foveal cystoid edema [2]. The grading scale was based on standard reference OCT images (Fig. 1).

Qualitative variables are presented as absolute counts and relative frequencies and were compared using Pearson's χ^2 test. To determine the appropriate format for presenting quantitative variables, normality of distribution was assessed using the Shapiro–Wilk W test. Quantitative variables are expressed as medians with the 25th and 75th percentiles. For comparison of quantitative variables between two independent groups, the nonparametric Mann–Whitney U test was used; for two related groups, the Wilcoxon signed-rank test was applied.

All *p*-values were two-sided. In all analyses, differences were considered statistically significant at $p < 0.05$. Statistical analyses were performed using SPSS 27.0.

Results. CRT among all patients enrolled in the study increased significantly from 256.3 [230.3–296.5] μm to 278.0 [242.0–311.0] μm ($p = 0.021$). Changes in CRT in the main and control groups before treatment and at 1, 3, and 6 months are presented in Table 2.

CRT was assessed separately in each group. In the control group (no SLC performed), CRT increased over the 6-month follow-up: before RT – 256.0 [229.8–283.0] μm; at 1 month – 267.0 [230.0–319.0] μm ($p = 0.005$); at 3 months – 285.0 [259.5–330.5] μm ($p < 0.001$); and at 6 months – 301.0 [259.5–330.5] μm ($p < 0.001$). In the main group (SLC performed), CRT did not change significantly: before RT – 285.0 [259.5–330.5] μm; at 1 month – 268.0 [238.3–306.3] μm ($p = 0.556$); at 3 months – 263.0 [230.3–285.5] μm ($p = 0.319$); and at 6 months – 266.0 [238.5–281.0] μm ($p = 0.387$).

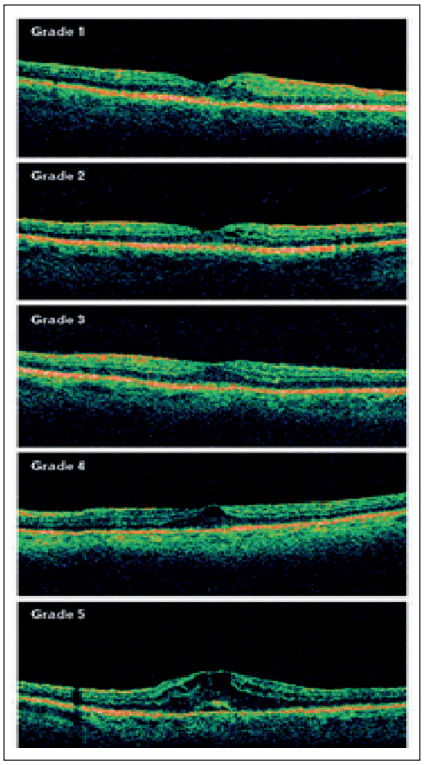

Fig. 1. OCT-based classification of radiation-induced macular edema

Table 2. **CRT in the main and control groups before treatment and at 1, 3, and 6 months after RT**

Patient group	CRT, μm			
	Before treatment	1 month	3 months	6 months
Main group	285.0 [259.5–330.5]	268.0 [238.3–306.3], $p = 0.556$	263.0 [230.3–285.5], $p = 0.319$	266.0 [238.5–281,0], $p = 0.387$
Control group	256.0 [229.8–283.0]	267.0 [230.0–319.0], $p = 0.005$	285.0 [259.5–330.5], $p < 0,001$	301.0 [259.0–384.0], $p < 0,001$
p (between groups)	0.574	0.946	0.017	0.004

When comparing CRT between the main and control groups, no significant difference was found at 1 month after RT: 268.0 [238.3–306.3] μm vs. 267.0 [230.0–319.0] μm, respectively ($p = 0.946$). At 3 months, CRT was 263.0 [230.3–285.5] μm in the main group and 285.0 [259.5–330.5] μm in the control group ($p = 0.017$); at 6 months, it was 266.0 [238.5–281.0] μm and 301.0 [259.0–384.0] μm, respectively ($p = 0.004$). Thus, at 3 and 6 months, CRT differences between the main and control groups were statistically significant, suggesting that early signs of radiation maculopathy were less pronounced in the main group. At 6 months after treatment, CRT in the control group was 35 μm (13.2 %) higher than in the main group ($p = 0.004$).

Radiation maculopathy was detected on OCT in 8 patients: 3 in the main group (11.1 %; 95 % CI, 3.9–28.1 %) and 5 in the control group (20.0 %; 95 % CI, 8.9–39.1 %; $p > 0.05$). In the main group, radiation maculopathy was first detected at 3 months in 1 patient after BT (grade I) and at 6 months in 2 patients (1 after BT, grade I; 1 after SRT, grade II). In the control group, signs of radiation retinopathy were observed as early as 1 month in 2 patients after SRT (grades II and III), at 3 months in 2 patients after BT and SRT (grades II and III, respectively), and at 6 months in 1 patient after BT (grade V; Table 3).

In the main group, signs of radiation maculopathy were less pronounced and were recorded in only 2 patients at 3 and 6 months of follow-up. In the control group (no prior SLC), manifestations of radiation maculopathy were recorded in 5 patients at 1, 3, and 6 months of follow-up.

Table 3. **Number of patients with signs of radiation retinopathy in the main and control groups**

Number of patients with signs of radiation retinopathy		After 1 month					After 3 months					After 6 months				
		Grade I	Grade II	Grade III	Grade IV	Grade V	Grade I	Grade II	Grade III	Grade IV	Grade V	Grade I	Grade II	Grade III	Grade IV	Grade V
Main group	BT						1					1				
	SRT												1			
Control group	BT							1								1
	SRT		1	1					1							

Clinical cases from a photo archive of radiation maculopathy based on OCT examination results in patients with CM are presented (Fig. 2, 3).

During the observation period of 1 to 2 months after RT, hypotensive therapy was prescribed due to ocular hypertension in 6 patients of the main group (1 patient with stage cT3N0M0 and 5 patients with stage cT2N0M0 after SRT) and in 7 patients of the control group (1 patient with stage cT3N0M0 after SRT, 4 patients with stage cT2N0M0 after SRT, and 1 patient with stage cT2N0M0 after BT).

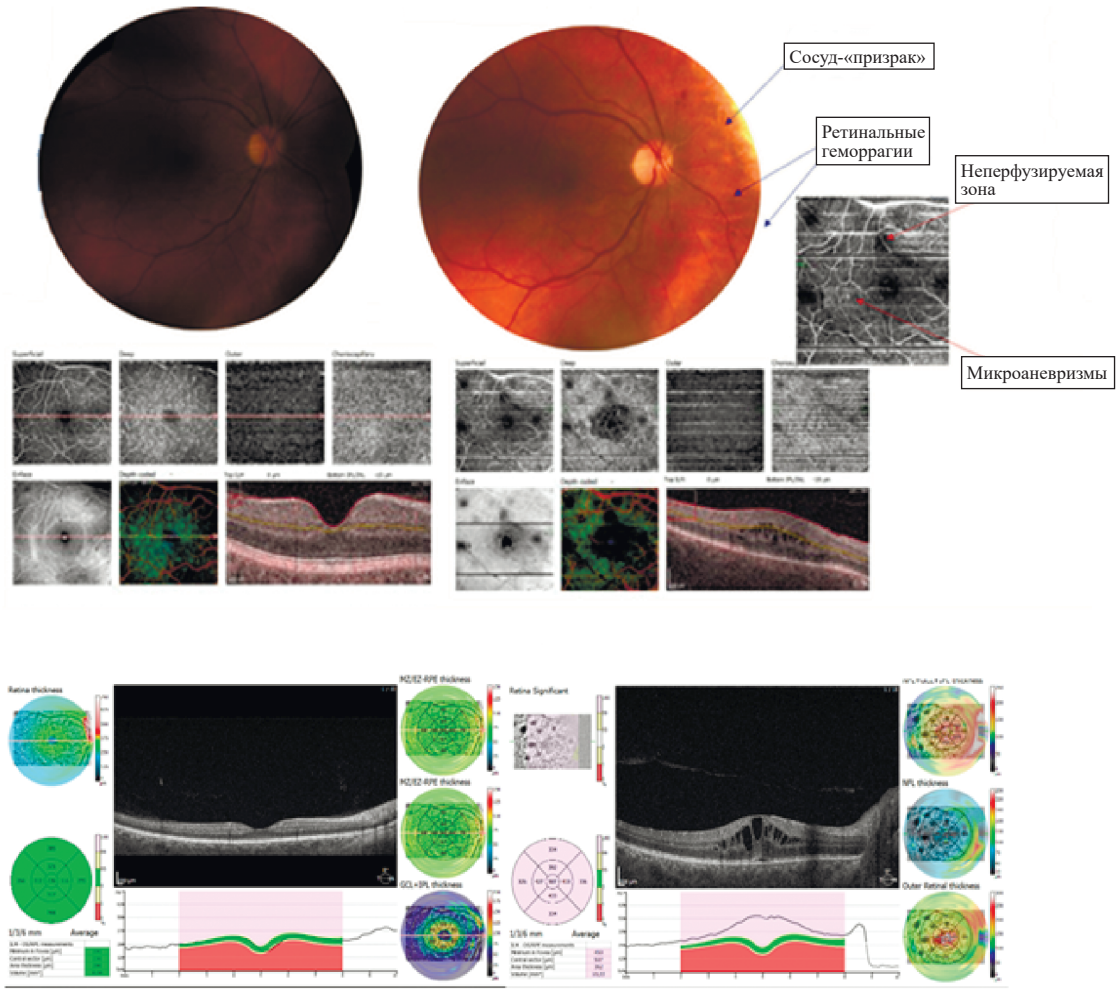

Fig. 2. Photo archive of OCT examination results in a patient with CM staged cT2N0M0: tumor thickness 5.3 mm, basal diameter 10.3 mm before and 6 months after BT; grade V radiation maculopathy developed

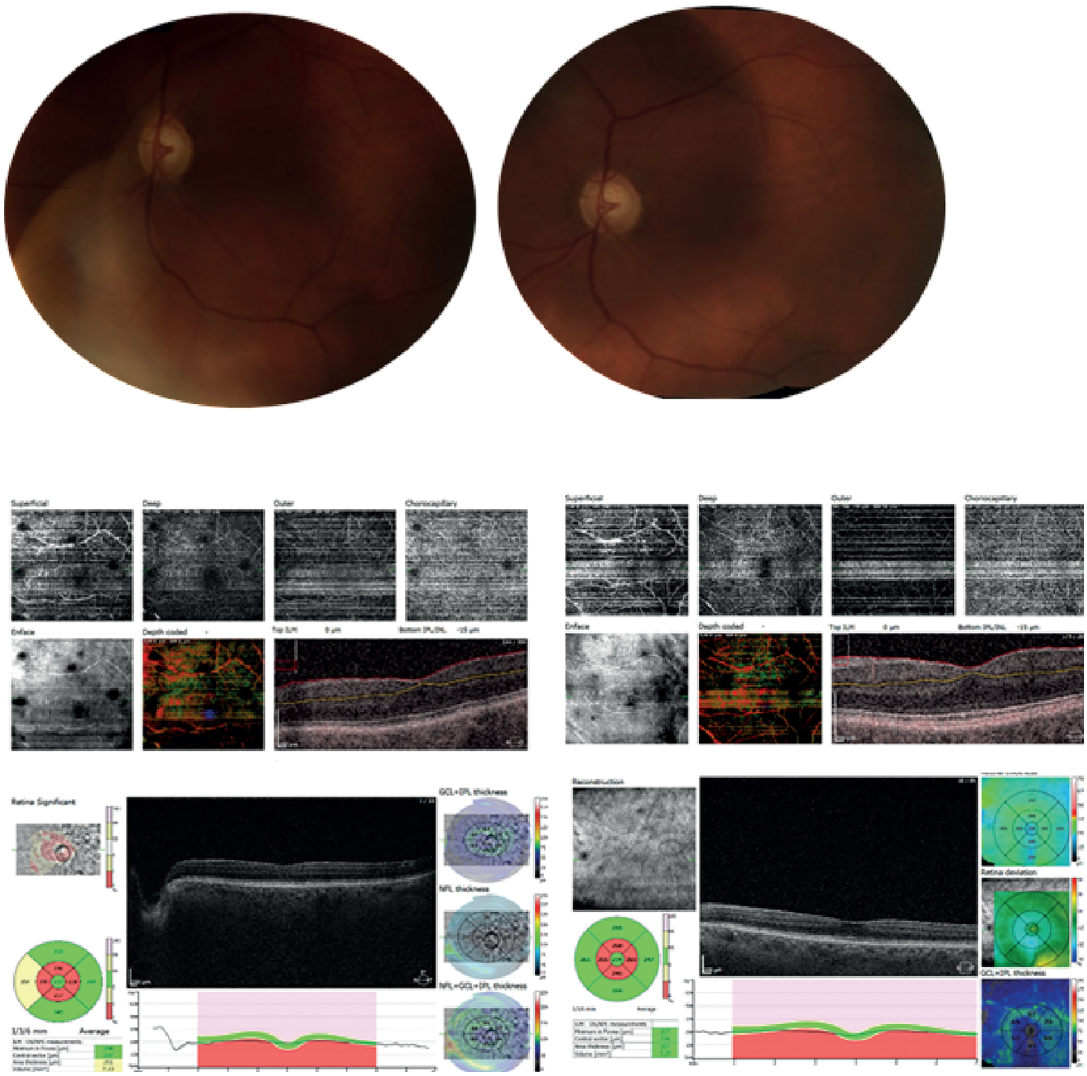

Fig. 3. Photo archive of OCT examination results in a patient from the main group with CM staged cT1N0M0: tumor thickness 1.3 mm, basal diameter 4.5 mm; before and 6 months after BT; grade I radiation maculopathy developed

Discussion. Radiation retinopathy is a chronic, progressive occlusive vasculopathy that can manifest at any time from 1 month to 15 years after RT [1, 3, 4]. It can lead to severe vision loss, up to complete blindness, and even to loss of the eye. There is an urgent need to develop and implement new effective and safe treatment methods to reduce the likelihood of radiation retinopathy. To this end, intravitreal injections of vascular endothelial growth factor (VEGF) inhibitors, sustained-release glucocorticoids (GC), and retinal photocoagulation (both focal and panretinal, depending on the clinical manifestations of retinopathy) are now used. However, the described invasive methods are associated with adverse effects, including ocular hypertension, complicated cataract, retinal detachment, hemorrhage, endophthalmitis, and cardiovascular complications [5–10].

There are currently no consensus guidelines for the treatment of radiation retinopathy.

The pathophysiological mechanisms underlying radiation retinopathy resemble those of diabetic retinopathy and involve elevated levels of VEGF and proinflammatory factors. These insights into the pathogenesis have prompted the use of VEGF inhibitors and GC [11–14]. VEGF inhibitors reduce vascular permeability and suppress neovascularization. However, these drugs may increase levels of proinflammatory factors such as interleukins (IL)-2, -6, and -8, and transforming growth factor-β2, a mediator of fibrosis and scar tissue contraction that indirectly contributes to retinal pigment epithelium tears and recurrent vitreoretinal hemorrhages. This may represent a compensatory response to VEGF inhibition.

GC exert anti-inflammatory effects by blocking cytokine production, inhibiting VEGF-A–induced leukocyte adhesion, reducing VEGF-A expression, restoring the integrity of the inner blood–retinal barrier by upregulating tight junction proteins, and increasing adenosine levels, thereby reducing osmotic swelling of Müller cells [15, 16]. Because systemic GC use carries risks such as hyperglycemia, and periocular administration does not ensure adequate intraocular concentrations, intravitreal injection is the preferred route of corticosteroid delivery. Intravitreal injections may increase the risk of posterior subcapsular cataract and elevated intraocular pressure (IOP) [17, 18].

Opinions on the use of GC in patients with CM undergoing RT differ among investigators. For example, C. L. Shields et al. (2005) studied the efficacy of intravitreal triamcinolone acetonide in 31 patients with CM after I-125 BT who developed clinical signs of radiation retinopathy 12–24 months after BT [19]. Clinical findings included slowly progressive occlusive retinal vasculopathy, intraretinal edema and exudation, hemorrhage, nerve fiber layer infarcts, and ultimately retinal atrophy. The radiation dose at the foveola ranged from 5,122 to 16,100 cGy, and the dose rate was 56 cGy/h. Triamcinolone was administered intravitreally at 4 mg. After injection, visual acuity improved by 2 Snellen lines in 68 % of patients at 1 month and in an additional 26 % at 6 months. OCT showed foveal edema in all patients before injection, with a mean foveal thickness of 417 μm; at 1 month, 46 % had a mean thickness of 207 μm, and at 6 months, 55 % had a mean foveolar thickness of 292 μm. Complete resolution of foveal edema at 3 and 6 months was observed in 50 % of patients. Low visual acuity (20/400 or worse) at the time of maculopathy detection was present in 23 % of patients; at 1 month post-injection, this proportion decreased to 18 %. The effect of triamcinolone acetonide gradually declined by 6 months, with 55 % of patients exhibiting low visual acuity. Over 6 months of follow-up, complications included transient, untreated IOP elevation in 16 %, persistent glaucoma requiring topical anti-glaucoma therapy in 10 %, and cataract in 10 %; 65 % of patients had no complications.

R. I. Kaplan et al. (2017) reported outcomes in 8 patients with radiation maculopathy refractory to anti-angiogenic therapy after I-125 BT [21]. The radiation dose to the tumor apex was 69.4 Gy (range 48.2–87.4), and to the fovea 81.5 Gy (range 22.7–138.2). Intravitreal triamcinolone acetonide 4 mg was administered. Stabilization or improvement of visual acuity was achieved in all patients at 3 months, in 88 % at 9 months, and in 75 % at 12 months. Reduction in CRT on OCT was observed in 75 % of patients at 1–6 months and in 88 % at 12 months. During a follow-up of 21 months (range 15–28), drug-induced ocular hypertension requiring topical therapy developed in 2 (25 %) patients, and cataract progression requiring surgery occurred in 1 (12 %) patient. No cases of endophthalmitis or retinal detachment were reported [20].

N. V. Shah et al. (2013) reported outcomes in 25 patients after I-125 BT who received intravitreal triamcinolone acetonide 4 mg [21]. Patients underwent 2 to 6 injections (median 2); in severe cases, 1.25 mg bevacizumab was added to triamcinolone (severe radiation maculopathy refractory to anti-angiogenic monotherapy). Mean visual acuity remained stable, while visual acuity improved in 36 % of patients; CRT decreased moderately. The follow-up period was 30 months (range 10–54). In 5 % of patients, IOP elevation necessitated hypotensive therapy.

J. M. Caminal et al. (2015) reported outcomes of a 0.7-mg dexamethasone implant in 12 patients with radiation maculopathy after BT [23]. After implantation, visual acuity improved from 1.0 ± 0.58 to 0.8 ± ± 0.58 logMAR, CRT decreased from 416 ± 263 μm to 254 ± 170 μm, and a significant reduction in retinopathy severity was observed. The follow-up was 8.2 ± 7.8 months. Ocular hypertension and cataract each developed in 8.3 % of patients [22]. L. Frizziero (2017), after intravitreal 0.7-mg dexamethasone implantation in 13 patients with radiation maculopathy following BT, observed an increase in visual acuity from 54 (36–65) letters to 61 (54–67) on the logMAR chart, and a reduction in foveal retinal thickness from 407 μm (357–524) to 370 μm (306–487) [23]. No complications were recorded during 6 months of follow-up.

Only one study, published by Horgan et al. in 2009, has evaluated periocular triamcinolone for prophylaxis of retinal edema after RT. In a randomized trial of 163 patients after I-125 BT, the authors demonstrated the efficacy of periocular triamcinolone injections (40 mg) in preventing macular edema over 18–24 months. Macular edema occurred in 12 % and 50 % of patients in the triamcinolone group at 12 and 24 months, respectively, compared with 42 % and 61 % in control groups without triamcinolone. The study showed a significantly lower risk of macular edema in the triamcinolone group: 36 % at 18 months versus 58 % in the control group [24].

Treatment of radiation retinopathy remains challenging for ocular oncologists because of its chronic, progressive course and the wide variability in time of onset (months to years after RT). OCT is widely used for diagnosis, treatment planning, and monitoring of macular edema associated with radiation retinopathy. In our study, we applied the classification proposed by N. Horgan et al. (2010) to grade the severity of macular edema in radiation retinopathy [2]. Advantages of this OCT-based classification include noninvasiveness and the repeatability and reproducibility of quantitative measurement of macular edema. To manage retinopathy, intravitreal injections of VEGF inhibitors and GC, as well as sectoral or panretinal laser coagulation (depending on retinal findings), are widely used. It should be noted that VEGF inhibitors may increase inflammation in ocular coats, and pharmacokinetic studies indicate that GC are completely eliminated from the eye only after 3 months. Intravitreal and periocular GC administration may be associated with adverse effects such as ocular hypertension, cataract, endophthalmitis, and others [5–10].

SLC performed before RT can significantly improve the efficacy of radiation treatment and reduce the incidence of radiation retinopathy. This method partially "switches off" the retinal microcirculatory network, targeting the pathogenetic mechanism of radiation vasculopathy and thereby reducing both the frequency and severity of radiation retinopathy. In our study, SLC reduced CRT by 35 μm (13.2 %) at 6 months after LT compared with the control group ($p = 0.004$).

Conclusion. SLC combined with intravitreal GC administration in patients with CM prior to RT demonstrated statistically significant efficacy in reducing CRT, thereby markedly decreasing the severity of radiation maculopathy.

Conflict of interest. The authors declare no conflict of interest.

References

1. García-O'Farrill N., Pugazhendhi S., Karth P. A., Hunter A. A. Radiation retinopathy intricacies and advances in management. *Seminars in Ophthalmology*, 2022, vol. 37, no. 4, pp. 417–435. https://doi.org/10.1080/08820538.2021.2000623

2. Horgan N., Shields C. L., Mashayekhi A., Shields J. A. Classification and treatment of radiation maculopathy. *Current Opinion in Ophthalmology*, 2010, vol. 21, no. 3, pp. 203–208. https://doi.org/10.1097/ICU.0b013e3283386687

3. Sahoo N. K., Ranjan R., Tyagi M., Agrawal H., Reddy S. Radiation Retinopathy: Detection and Management Strategies. *Clinical Ophthalmology*, 2021, vol. 15, pp. 3797–3809. https://doi.org/10.2147/OPTH.S219268

4. Stoyukhina A. S. Evaluation of the effectiveness of organ-preserving treatment of choroidal melanomas based on optical coherence tomography data. *Vestnik oftal'mologii = Russian Annals of Ophthalmology*, 2021, vol. 137, no. 5, pt. 2, pp. 189–200 (in Russian).

5. Shields C. L., Dalvin L. A., Chang M., Mazloumi M., Fortin P., McGarrey M., Martin A., Yaghy A., Yang X., Vichitvejpaisal P., Mashayekhi A., Shields J. A. Visual Outcome at 4 Years Following Plaque Radiotherapy and Prophylactic Intravitreal Bevacizumab (Every 4 Months for 2 Years) for Uveal Melanoma: Comparison with Nonrandomized Historical Control Individuals. *JAMA Ophthalmology*, 2020, vol. 138, no. 2, pp. 136–146. https://doi.org/10.1001/jamaophthalmol.2019.5132

6. Fallico M., Chronopoulos A., Schutz J. S., Reibaldi M. Treatment of radiation maculopathy and radiation-induced macular edema: A systematic review. *Survey of Ophthalmology*, 2021, vol. 66, no. 3, pp. 441–460. https://doi.org/10.1016/j.survophthal.2020.08.007

7. Maheshwari A., Finger P. T. Regression patterns of choroidal melanoma: After palladium-103 (^{103}Pd) plaque brachytherapy. *European Journal of Ophthalmology*, 2018, vol. 28, no. 6, pp. 722–730. https://doi.org/10.1177/1120672118776146

8. Miguel D., de Frutos-Baraja J. M., López-Lara F., Saornil M. A., García-Álvarez C., Alonso P., Diezhandino P. Radiobiological doses, tumor, and treatment features influence on outcomes after episcleral brachytherapy. A 20-year retrospective analysis from a single-institution: part II. *Journal of Contemporary Brachytherapy*, 2018, vol. 10, no. 4, pp. 347–359. https://doi.org/10.5114/jcb.2018.77955

9. Naumenko L. V. The Profiles of Morbidities Related to Brachytherapy Administered to Choroid Melanoma Patients and the Contribution of Delimiting Laser Photocoagulation to Their Prevention. *Oftal'mologiya Vostochnaya Evropa = Ophthalmology Eastern Europe*, 2021, vol. 11, no. 3, pp. 283–293 (in Russian).

10. Murray T. G., Latiff A., Villegas V. M., Gold A. S. Aflibercept for radiation maculopathy study: a prospective, randomized clinical study. *Ophthalmology. Retina*, 2019, vol. 3, no. 7, pp. 561–566. https://doi.org/10.1016/j.oret.2019.02.009

11. Finger P. T., Chin K. J. High-dose (2.0 mg) intravitreal ranibizumab for recalcitrant radiation retinopathy. *European Journal of Ophthalmology*, 2013, vol. 23, no. 6, pp. 850–856. https://doi.org/10.5301/ejo.5000333

12. Schefler A. C., Fuller D., Anand R., Fuller T., Moore C., Munoz J., Kim R. S. Randomized Trial of Monthly Versus As-Needed Intravitreal Ranibizumab for Radiation Retinopathy–Related Macular Edema: 1-Year Outcomes. *American Journal of Ophthalmology*, 2020, vol. 216, pp. 165–173. https://doi.org/10.1016/j.ajo.2020.03.045

13. Horooghian F., Kertes P. J., Eng K. T., Agrón E., Chew E. Y. Alterations in the intraocular cytokine milieu after intravitreal bevacizumab. *Investigative Ophthalmology and Visual Science*, 2010, vol. 51, no. 5, pp. 2388–2392. https://doi.org/10.1167/iovs.09-4065

14. Zhang X., Wang N., Schachat A. P., Bao S., Gillies M. C. Glucocorticoids: structure, signaling and molecular mechanisms in the treatment of diabetic retinopathy and diabetic macular edema. *Current Molecular Medicine*, 2014, vol. 14, no. 3, pp. 376–384. https://doi.org/10.2174/1566524014666140128114414

15. Brovkina A. F., Kabardikova L. A., Shcherbakov P. A., Bure I. V., Mirzaev K. B. Uveal melanoma and its local inflammation – good or bad for the patient? *Vestnik oftal'mologii = Russian Annals of Ophthalmology*, 2025, vol. 141, no. 1, pp. 5–12 (in Russian).

16. Jeon S., Lee W. K. Effect of intravitreal triamcinolone in diabetic macular edema unresponsive to intravitreal bevacizumab. *Retina*, 2014, vol. 34, no. 8, pp. 1606–1611. https://doi.org/10.1097/IAE.0000000000000109

17. Chu Y. K., Chung E. J., Kwon O. W., Lee J. H., Koh H. J. Objective evaluation of cataract progression associated with a high dose intravitreal triamcinolone injection. *Eye (London)*, 2008, vol. 22, no. 7, pp. 895–899. https://doi.org/10.1038/sj.eye.6702802

18. Smithen L. M., Ober M. D., Maranan L., Spaide R. F. Intravitreal triamcinolone acetonide and intraocular pressure. *American Journal of Ophthalmology*, 2004, vol. 138, no. 5, pp. 740–743. https://doi.org/10.1016/j.ajo.2004.06.067

19. Shields C. L., Demirci H., Dai V., Marr B., P., Mashayekhi A., Materin M. A., Manquez M. E., Shields J. A. Intravitreal triamcinolone acetonide for radiation maculopathy after plaque radiotherapy for choroidal melanoma. *Retina*, 2005, vol. 25, no. 7, pp. 868–874. https://doi.org/10.1097/00006982-200510000-00009

20. Kaplan R. I., Chaugule S. S., Finger P. T. Intravitreal triamcinolone acetate for radiation maculopathy recalcitrant to high-dose intravitreal bevacizumab. *The British Journal of Ophthalmology*, 2017, vol. 101, no. 12, pp. 1694–1698. https://doi.org/10.1136/bjophthalmol-2017-310315

21. Shah N. V., Houston S. K., Markoe A., Murray T. G. Combination therapy with triamcinolone acetonide and bevacizumab for the treatment of severe radiation maculopathy in patients with posterior uveal melanoma. *Clinical ophthalmology*, 2013, vol. 7, pp. 1877–1882. https://doi.org/10.2147/OPTH.S47684

22. Caminal J. M., Flores-Moreno I., Arias L., Gutiérrez C., Piulats J. M., Català J., Rubio M. J., Cobos E., García P., Pera J., Giralt J., Arruga J. Intravitreal dexamethasone implant for radiation maculopathy secondary to plaque brachytherapy in choroidal melanoma. *Retina*, 2015, vol. 35, no. 9, pp. 1890–1897. https://doi.org/10.1097/IAE.0000000000000537

23. Frizziero L., Parrozzani R., Trainiti S., Pilotto E., Miglionico G., Pulze S., Midena E. Intravitreal dexamethasone implant in radiation-induced macular oedema. *The British Journal of Ophthalmology*, 2017, vol. 101, no. 12, pp. 1699–1703. https://doi.org/10.1136/bjophthalmol-2017-310220

24. Horgan N., Shields C. L., Mashayekhi A., Salazar P. F., Materin M. A., O'Regan M., Shields J. A. Periocular triamcinolone for prevention of macular edema after plaque radiotherapy of uveal melanoma: a randomized controlled trial. *Ophthalmology*, 2009, vol. 116, no. 7, pp. 1383–1390. https://doi.org/10.1016/j.ophtha.2009.01.015

Information about the authors

Olga M. Holub – Ophthalmologist. Minsk Regional Children's Clinical Hospital (19B/5, Frunzenskaya Str., Borovlyany village, 223053, Minsk District, Republic of Belarus). E-mail: holub_o@mail.ru. https://orcid.org/0009-0006-9968-4861

Larisa V. Naumenko – D. Sc. (Med.), Associate Professor, Leading Researcher. N. N. Alexandrov National Cancer Centre of Belarus (Lesnoy, 223040, Minsk District, Republic of Belarus). Email: larisanau@mail.ru. http://orcid.org/0000-0002-1875-9176

Sergey A. Krasny – Academician, D. Sc. (Med.), Professor, Deputy Director. N. N. Alexandrov National Cancer Centre of Belarus (Lesnoy, 223040, Minsk District, Republic of Belarus). E-mail: info@omr.by. http://orcid.org/0000-0003-3244-5664.

Ekaterina P. Zhylyayeva – Ph. D. (Med.), Ophthalmologist. N. N. Alexandrov National Cancer Centre of Belarus (Lesnoy, 223040, Minsk District, Republic of Belarus). E-mail: kukuuu@yandex.by. http://orcid.org/0000-0003-2964-6895

Galina A. Sushchenya – Ph. D. (Med.), Ophthalmologist. Minsk Regional Children's Clinical Hospital (19B/5, Frunzenskaya Str., Borovlyany village, 223053, Minsk District, Republic of Belarus). E-mail: halina.sushcheia@yandex.ru. https://orcid.org/0000-0003-2427-1967

Alesya A. Evmenenko – Ph. D. (Med.), Specialist of the Statistics and Analysis group. N. N. Alexandrov National Cancer Centre of Belarus (Lesnoy, 223040, Minsk District, Republic of Belarus). E-mail: evmenenkoalesya88@gmail.com. https://orcid.org/0000-0001-6335-1404

Информация об авторах

Голуб Ольга Михайловна – врач–офтальмолог. Минская областная детская клиническая больница (ул. Фрунзенская, 19Б/5, 223053, д. Боровляны, Минский р-н, Республика Беларусь). E-mail: holub_o@mail.ru. https://orcid.org/0009-0006-9968-4861

Науменко Лариса Владимировна – д-р мед. наук, доцент, вед. науч. сотрудник. РНПЦ онкологии и медицинской радиологии им. Н. Н. Александрова (аг. Лесной, 223040, Минский р-н, Республика Беларусь). E-mail: larisanau@mail.ru. http://orcid.org/0000-0002-1875-9176

Красный Сергей Анатольевич – академик, д-р мед. наук, профессор, заместитель директора. РНПЦ онкологии и медицинской радиологии им. Н. Н. Александрова (аг. Лесной, 223040, Минский р-н, Республика Беларусь). E-mail: info@omr.by. http://orcid.org/0000-0003-3244-5664

Жиляева Екатерина Павловна – канд. мед. наук, врач-офтальмолог. РНПЦ медицинской радиологии им. Н. Н. Александрова (аг. Лесной, 223040, Минский р-н, Республика Беларусь). E-mail: kukuuu@yandex.by. http://orcid.org/0000-0003-2964-6895

Сущеня Галина Анатольевна – канд. мед. наук, врач–офтальмолог. Минская областная детская клиническая больница (ул. Фрунзенская, 19Б/5, 223053, д. Боровляны, Минский р-н, Республика Беларусь). E-mail: halina.sushcheia@yandex.ru https://orcid.org/0000-0003-2427-1967

Евмененко Алеся Александровна – канд. мед. наук, специалист группы статистики и анализа. РНПЦ онкологии и медицинской радиологии им. Н. Н. Александрова (аг. Лесной, 223040, Минский р-н, Республика Беларусь). E-mail: evmenenkoalesya88@gmail.com. http://orcid.org/0000-0001-6335-1404